

# IRIDOLOGY

## PHYSIOLOGY OF IRIS SIGNS

Compiled by

Campbell M Gold

(2006)

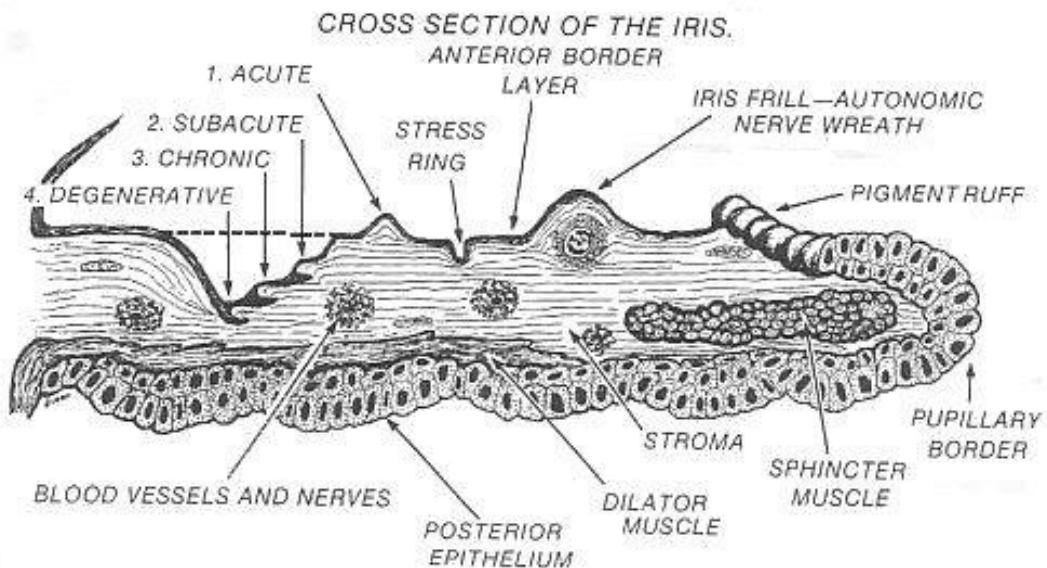
CMG Archives

<http://campbellmgold.com>

--()---

### Introduction

The picture below illustrates a cross section of the iris tissues, and is a representation of how discrete iris signs (lesion, lacuna, crypt, etc) are formed within and upon the iris tissues. The fibres running radially from the pupil are known as 'trabeculae', and they form the body of the uppermost iris layers. These fibres rise and fall according to their reflex tissue-condition signals (levels of dis-ease in the relevant organ/area), and consequently, areas of light and levels of darkness result.



A primary theory of Iridology is that the iris is constructed in layers that represent the four stages of tissue activity, namely acute changes, sub-acute changes, chronic changes, and degenerative changes.

By noting which layer has the defect, the iridologist can suggest what the nature of the problem is. Consequently, iridology measures reflex tissue-conditions in four stages:

- 1) Acute Stage
- 2) Subacute Stage
- 3) Chronic Stage
- 4) Degenerative Stage

## 1) Acute Stage

This is when body tissue is active, inflamed and possibly painful, and is using nutrients at a high rate. The iris records this condition by being **very white** in the corresponding reflex area. This sign (areas of whiteness) is associated with catarrh and mucus eliminations, irritation of tissues, swellings, and sensitivity. This is the active or acute stage when the body is eliminating toxic accumulations and cleaning house.

Areas of lightness occur when the fibres rise up from the surface of the iris and appear to be white in colour (in reality they are transparent).

## 2) Subacute Stage

This is when nerve supply is exhausted, nutrients depleted, and circulation has slowed down because of fatigue, the acutely-active tissue slumps into a state of under-activity. This is called a subacute condition, and is seen as a **darkening** of that which was once 'very white' (see 'acute stage'), and the situation now exists where tissue integrity is significantly lowered.

However, the iridologist should be aware that it is not unusual for an individual to be born with this level (subacute indications) already present in certain organs/areas, because of inherent weakness being passed genetically from parent to child.

In the subacute condition, tissue vitality is much lower than it should be, available nutrients are not being properly absorbed, and the tissue cannot retain the nutrients.

Iridology and nutrition are symbiotically associated, and the iridologist should be aware that all 'dis-ease' conditions have a nutritional aspect to them. When the iridologist sees 'weak tissue', they are also seeing nutritional imbalance in that tissue. This is where iridology has one of its greatest uses; identifying weak tissue, and identifying where and what kind of nutrition is needed for specific correction.

If a subacute condition is left unaddressed, and the individual continues in an imprudent and stressful lifestyle, the condition will eventually degenerate further. Consequently, tissue integrity will move into a chronic condition where malnutrition takes a severe toll.

## 3) Chronic Stage

In the chronic stage, metabolic waste is not being eliminated, cellular activity has become congested, nerve impulses are deadened, and conditions are conducive for serious illness and disease to flourish. Consequently, the individual could develop a host of maladies to which an endless list of disease/pathological names are attached. It is estimated that 80% of illnesses in western society are of a chronic nature.

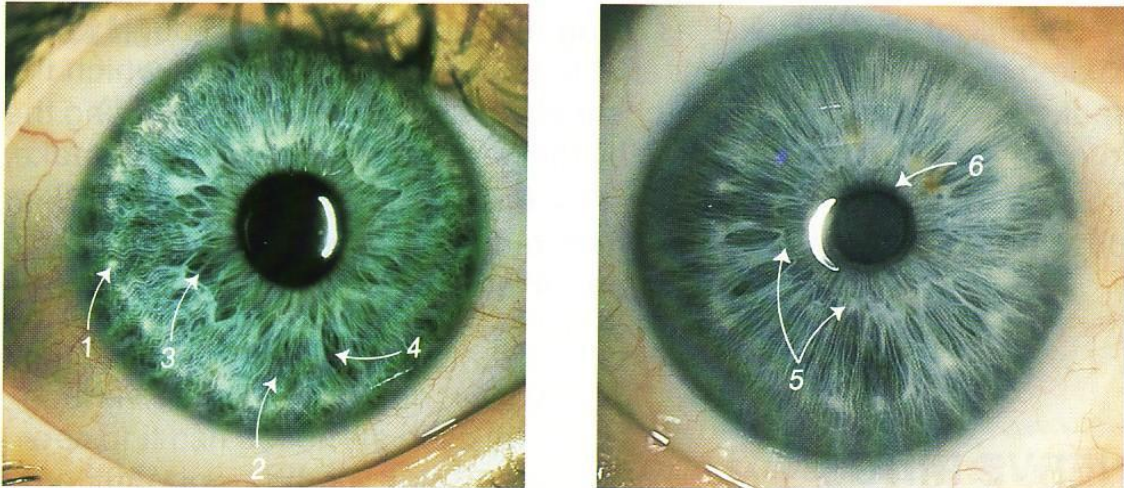
Attempting to correct a chronic condition is difficult, and will take perseverance and a shift to healthier patterns and habits of living. Unfortunately, it is much easier to maintain good health than it is to regain it when it has been lost or compromised. When a chronic condition is not addressed, and devitalizing activities/pathologies continue, the individual will be faced with the final stage of tissue decline – degeneration, decay, and necrosis. This is known as the degeneration stage.

## 4) Degeneration Stage

The degeneration stage appears in the iris as black holes where the fibres have simply disappeared from view. This indicates a serious condition that may be very difficult to reverse.

### Acute to Degenerative Iris Indications

(Pictures below – Four stages of tissue imbalance)



*THE FOUR STAGES AS THEY APPEAR IN THE IRIS. 1—ACUTE, 2—SUBACUTE, 3—CHRONIC, 4—DEGENERATIVE. NUMBER 5 DESIGNATES THE AUTONOMIC NERVE WREATH AND 6 IS THE PUPILLARY MARGIN.*

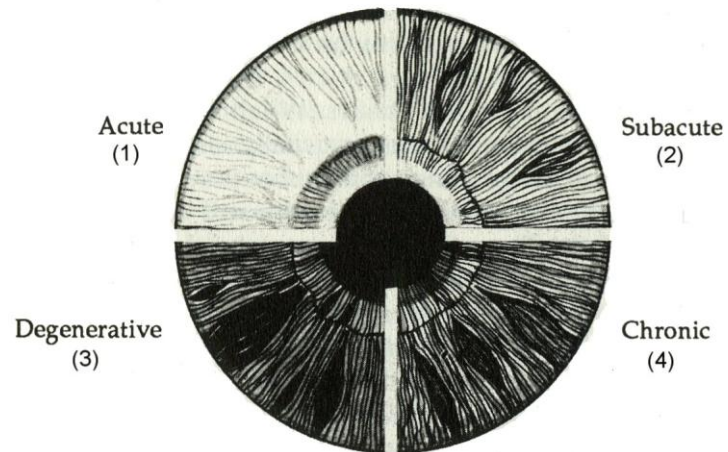
Note: 'Autonomic Nerve Wreath' is another term for 'Iris Wreath'.

### Summary

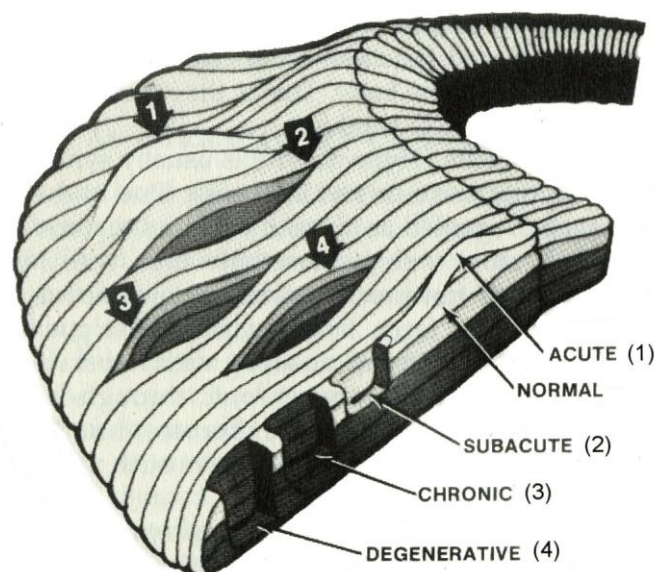
- **Acute:** a highly active stage with a short course - rapid metabolism with rapid use of nutrients, and rapid production of waste material.
- **Subacute:** between acute and chronic - a moderate amount of metabolic activity, which is slightly under normal.
- **Chronic:** persevering for a long time - an unhealthy state showing little change, or slow progress over a long period of time - a weak cell metabolism where cells do not take in nutrients or excrete wastes effectively.
- **Degenerative:** tissue destruction as cell metabolism becomes overloaded with wastes and unable to take in new nutrients - this is usually associated with an insufficient amount of metabolism to the indicated area, and a loss of function.

## Acute to Degenerative Iris Indications

(Picture below – Four Stages of Tissue Imbalance)



Above are the four stages of tissue imbalance—acute, subacute, chronic, and degenerative—viewed side by side. Below, the four stages, along with normal tissue, are shown as they appear in the iris fibers.



White, dark (grey or dirty looking), and black markings on the iris indicate activity (**acute**, **subacute**, **chronic**, and **degenerative**) or inflammation related to the relevant area, system, or function.

**White markings** (small dots or lines) relate to **acute** conditions, and indicate:

- Acute inflammation
- Hyperactivity

- Irritation
- Over-reaction

**Dark markings** (shades of grey or 'dirty looking') relate to **subacute** or **chronic** conditions, and indicate:

- Under-activity
- Stagnation
- Atrophy

Regarding dark markings, many iridologists recognise two shades of grey, light and dark. Light grey markings correspond to **subacute** conditions, and dark grey markings correspond to **chronic** conditions.

**Black markings** related to **degenerative** conditions and indicate:

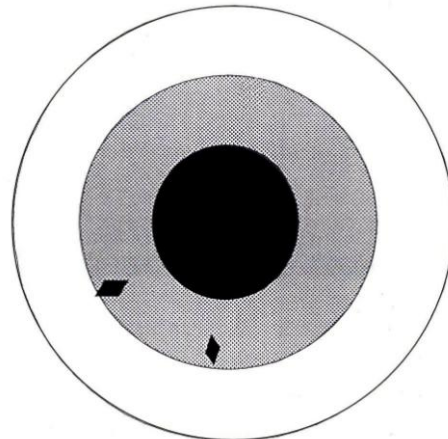
- No activity
- Loss of function
- Functional scarring

For example, after surgery, the individual will register a black marking/line in the relevant system area, which will fade after a short period.

### Reviewing the Markings

The four designations of tissue imbalance, typically used by iridologists are:

- 1) **Acute** – white
- 2) **Subacute** – light grey
- 3) **Chronic** – dark grey
- 4) **Degenerative** - black

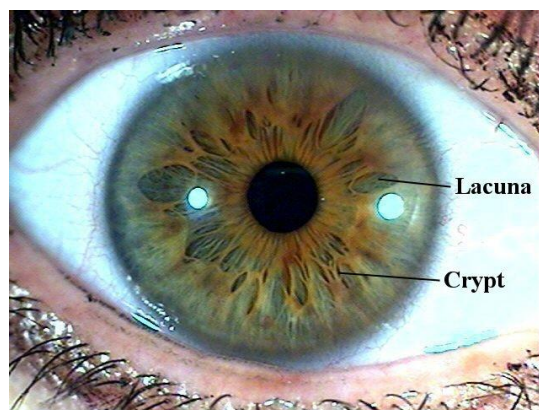


Regarding the stages of tissue imbalance, crypt colour is interpreted as follows:

(Picture right – Crypts)

- **Colourless** or same colour as surrounding iris – indicates that there is the potentiality for illness/pathology in the associated area
- **Whitish** – indicates that acute lesions are developing
- **Dark** and developing to a reddish or brown hue – indicates a chronic condition

(Picture right – Crypts)



- **Black** – indicates lesions, which have burned out with scar formation. This indicates a degenerative condition.

### **Acute to Degenerative Iris Indications - the Role of Iridology**

There is no perfect iris, and all individuals exhibit some degree of tissue weakness, whether genetically developed or determined. Frequently, combinations of tissue condition-stages (acute, subacute, chronic, and degenerative) within the same organ/area are observed. Tissue that is chronically ill, mixed with tissue that is highly acute, will produce an overall result of functional normalcy. For example, bi-lobed organs (e.g. lungs, kidneys, thyroid, etc) can exhibit a hyper-condition (over-active) on one side and a hypo-condition (under-active) on the other, thus producing an overall result of 'lab-tested' normalcy. The iridologist can confirm information that can help to remove confusion in these matters by indicating the isolated/individual conditions.

Iridology does not name diseases; instead, tissue condition is noted and interpreted. From this information, predisposition, tendency, and direction towards or away from pathological conditions are noted. Additionally, levels of toxin/drug settlement and accumulation are also observable.

Additionally, iridology also reveals the individual's constitutional makeup, which is valuable when trying to determine an individual's healing ability and response to treatment types. This gives the practitioner an indication of the individual's recuperative quality, how quickly a treatment type can be applied, and in what quantities the body can reasonably utilise any specific treatment/medication.

### **Forewarning**

However, the greatest asset of iridology is its ability to forewarn of approaching disease/imbalance. Tissue changes can be observed to occur before physical symptoms are actually manifested. This is a powerful tool when applied to preventive health care.

### **Healing Reflex**

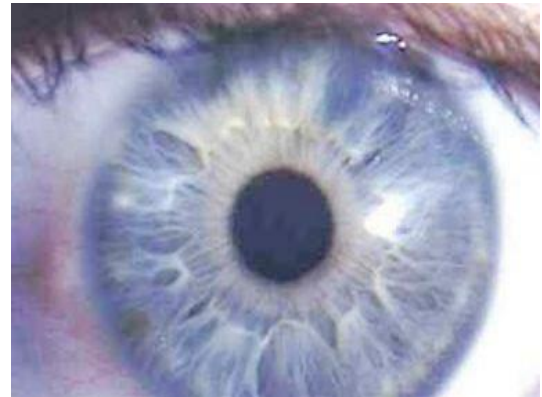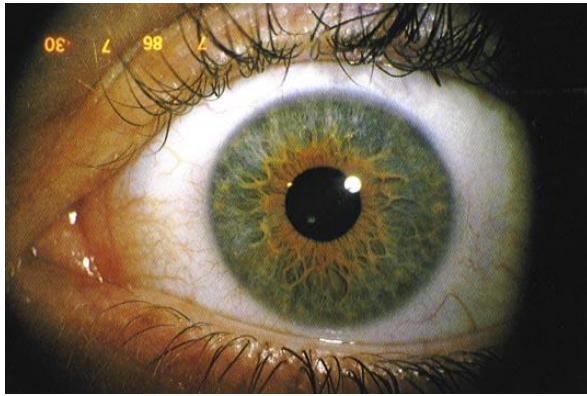
Conversely to the degeneration process, as healing advances, a reversal of the tissue reflex occurs, and this can be readily monitored/noted in the iris.

### **Other Examples of Iris-Sign Physiology**

#### **Lesions**

#### **Terminology Note (Lesion/Lacuna/Crypt/Defect Mark):**

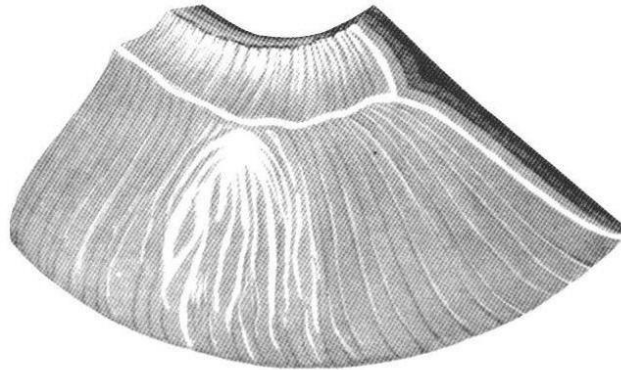
'Lesion' is an older term used in Jensen-type Iridology referring to pathology/weakness (inherited or developed) of some kind as noted in the irises, and marked by what is now termed as **Lacunae**, **Crypts**, or **Defect Marks**.



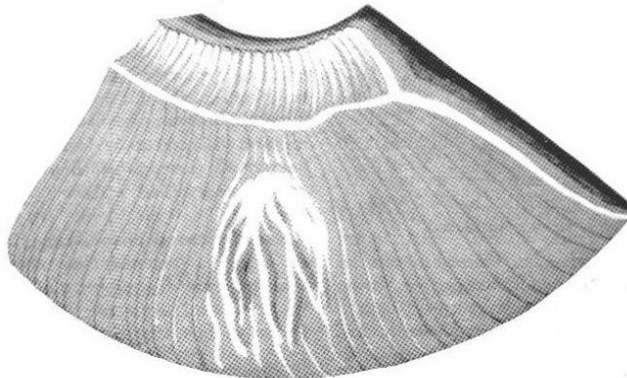
(Pictures above – Lesion Examples)

(Pictures below – Lesion Physiology)

**Open Lesion – Acute (typically white in colour)**



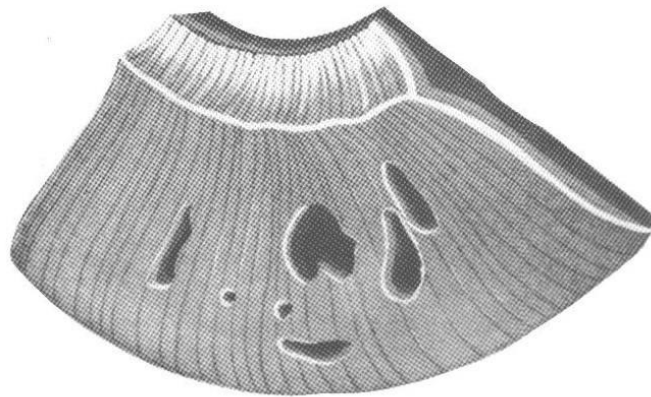
**Open Lesion – Subacute (typically light-grey in colour)**



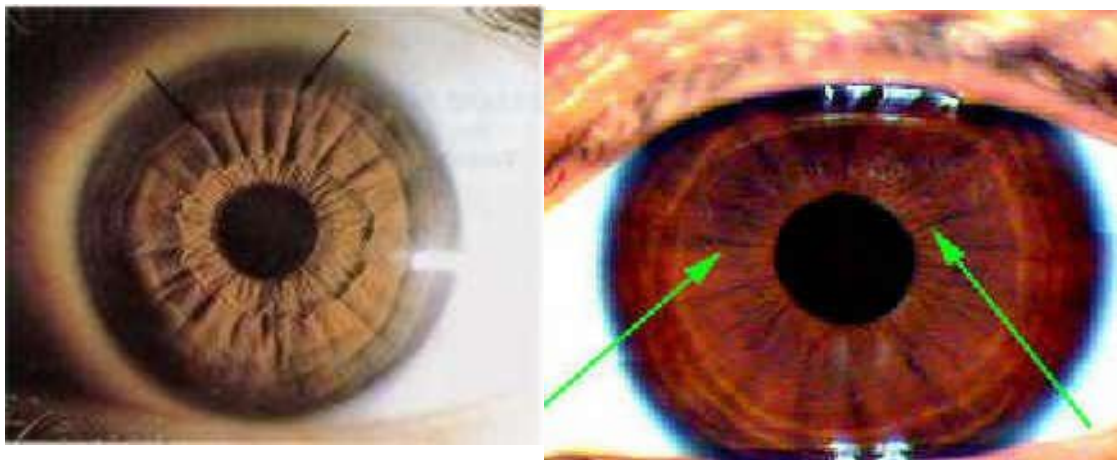
**Open Lesion – Chronic (typically dark-grey or very dark-grey in colour)**



**Closed Lesion – Degenerative (typically black in colour)**




**Radii Solaris**



(Pictures above – Radii Solaris Examples)

(Picture below – Radii Solaris Physiology)



End

--()--

<http://campbellmgold.com>

31082010/1