

IRIDOLOGY

BREAST CANCER

Compiled by

Campbell M Gold

(2006)

CMG Archives
<http://campbellmgold.com>

--()--

IMPORTANT

The health information contained herein is not meant as a substitute for advice from your physician, or other health professional. The following material is intended for general interest only; and it should not be used to diagnose, treat, or cure any condition whatever. If you are concerned about any health issue, symptom, or other indication, you should consult your regular physician, or other health professional. Consequently, the Author cannot accept responsibility for any individual who misuses the information contained in this material. Thus, the reader is solely responsible for all of the health information contained herein. However, every effort is made to ensure that the information in this material is accurate; but, the Author is not liable for any errors in content or presentation, which may appear herein.

--()--

Introduction

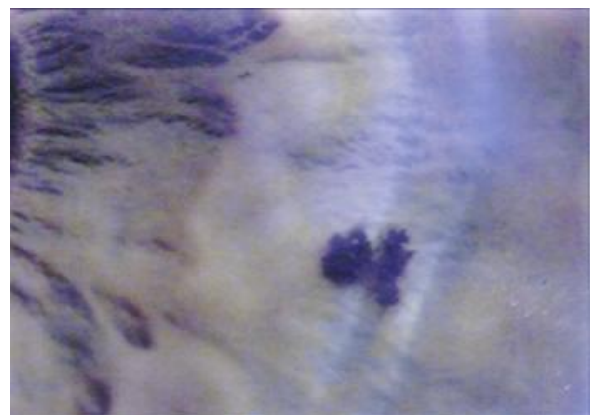
Ductal carcinomas account for 75% of all breast cancer; lobular and nipple carcinomas account for most of the remaining 25%.

Causes and Incidence

The cause of breast cancer is unknown, and 70% of women diagnosed with the disorder show none of the known risk factors, which include familial history; early menarche or late menopause; nulliparity or first child born after age 30; exposure to ionizing radiation; personal history of cancer or atypical hyperplasia; high-fat diet; and excessive alcohol consumption.

(Picture right - Nodules indicated at right breast)

Breast cancer is the most common cancer among women, with more than 182,000 new cases diagnosed each year. The incidence is twice as high for women over 65 years of age as for those in the 45 to 64 age group. The incidence is rising, particularly among black women; however, the mortality rate has remained fairly stable.

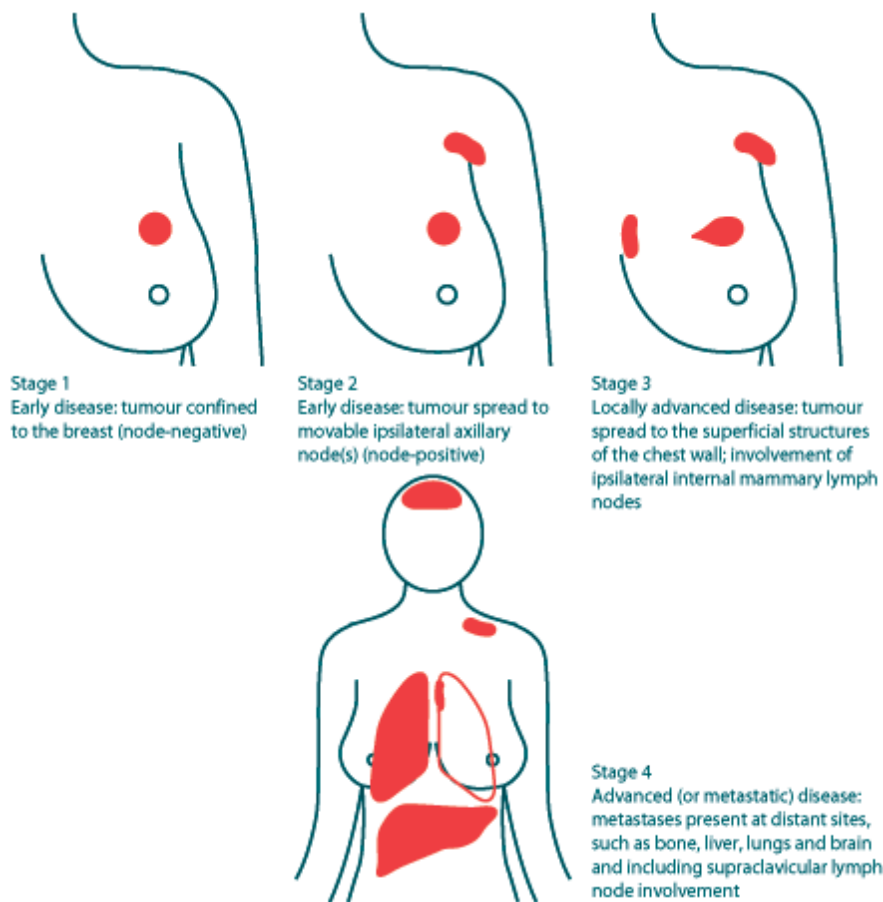


Disease Process

Ductal carcinomas originate in the lactiferous ducts, where the cancer cells form a dense fibrotic core with radiating tentacles that invade surrounding breast tissue. The tumor mass is generally solid, non-mobile, irregularly shaped, poorly defined, and unilateral. Lobular carcinomas originate in the breast lobules and are bilateral. Nipple carcinomas originate in the nipple complex and often occur in

conjunction with invasive ductal carcinomas. The lungs, bones, brain, and liver are common sites of breast cancer metastasis.

(Picture below - Disease Progress)



Symptoms

The most common presenting sign is a lump in the breast. About 50% are found in the upper outer quadrant. Nipple discharge may be present. Pain, tenderness, changes in breast shape, dimpling, and nipple retraction rarely occur until the disease reaches an advanced stage.

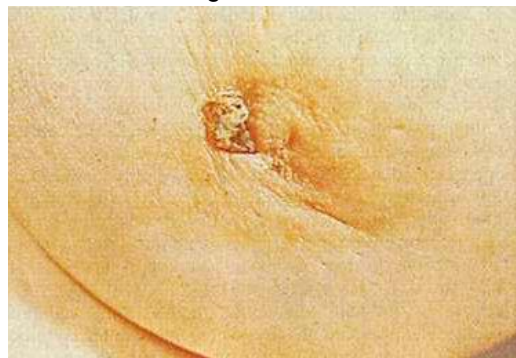(Picture right - Breast Cancer)

Potential Complications

The prognosis dims markedly as the number of involved lymph nodes increases. Pleural effusion, ascites, pathologic fracture, and spinal compression can occur with advanced disease.

Diagnostic Tests

A mass detected by breast self-examination, physical examination, or mammogram needs further follow-up. Definitive diagnosis is made by incisional, excisional, or needle biopsy of the mass.



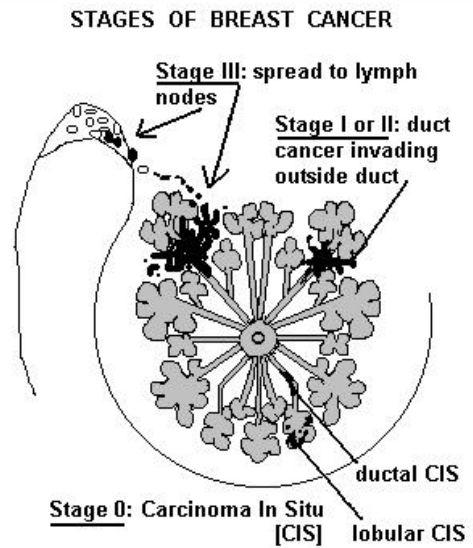
Treatments

Surgery - treatment of choice is resection of the lump with removal of a varying amount of surrounding healthy tissue, ranging from a margin of breast tissue to the entire breast, axillary lymph nodes, mammary lymphatic chain, and pectoral muscles; breast reconstruction

Drugs - adjunct systemic multidrug chemotherapy used primarily for premenopausal node-positive women; adjunct hormone therapy used primarily for postmenopausal node or receptor-positive women

General - radiation used as adjunct after surgery and for palliation in advanced disease; counseling for altered body image; recovery support groups; instruction in breast self-examination

End



--()--

<http://campbellmgold.com>

26082010/1