

GLAUCOMA

An Overview

Compiled by

Campbell M Gold

(2004)

CMG Archives

<http://campbellmgold.com>

--()--

IMPORTANT

The health information contained herein is not meant as a substitute for advice from your physician, or other health professional. The following material is intended for general interest only; and it should not be used to diagnose, treat, or cure any condition whatever. If you are concerned about any health issue, symptom, or other indication, you should consult your regular physician, or other health professional. Consequently, the Author cannot accept responsibility for any individual who misuses the information contained in this material. Thus, the reader is solely responsible for all of the health information contained herein. However, every effort is made to ensure that the information in this material is accurate; but, the Author is not liable for any errors in content or presentation which may appear herein.

--()--

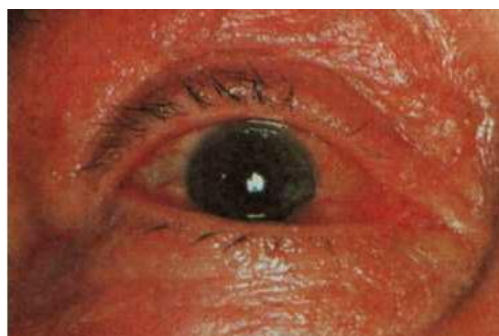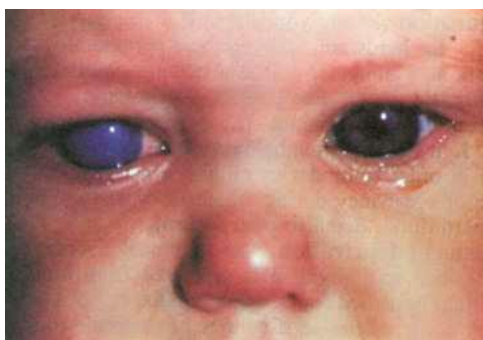Definition

Glaucoma (after Mosby), is an abnormal condition of high pressure within an eye. It is caused by a blocking of the normal flow of the watery fluid in the space between the cornea and lens of the eye (aqueous humour). Acute (angle-closure, closed-angle, or narrow-angle) glaucoma happens if the pupil in an eye with a narrow angle between the iris and cornea opens too wide and causes the folded iris to block the flow of aqueous humour. Chronic (open-angle or wide-angle) glaucoma is much more common, often occurring in both eyes; it develops slowly and is an inherited disease. Acute glaucoma happens with extreme eye pain, blurred vision, a red eye, and an abnormally wide-open pupil. Nausea and vomiting may occur. If untreated, acute glaucoma results in complete and permanent blindness within 2 to 5 days. Chronic glaucoma may show no symptoms except for gradual loss of side vision over a period of years. Sometimes headaches, blurred vision, and dull pain in the eye are present. Halos around lights and blind spots in the centre of the field of vision begin to occur after the condition has developed for a while.

Acute glaucoma is treated with eye drops to close the pupil and draw the iris away from the cornea, drugs that lower pressure, drugs that reduce fluid in the eye, and surgery to produce a pathway for aqueous humour. Chronic glaucoma can usually be controlled with eye drops.

All adults should have their eyes examined for glaucoma every three to five years. It is also a good idea for patients who have glaucoma to wear a medical identification tag.

Thus, Glaucoma is a disorder in which increased intraocular pressure leads to eventual vision impairment and possibly to degeneration of the optic nerve. It may be a primary condition, or it may be secondary to other ocular disease. Glaucoma is classified as open angle, or closed angle (Pictures below - Acute Glaucoma).

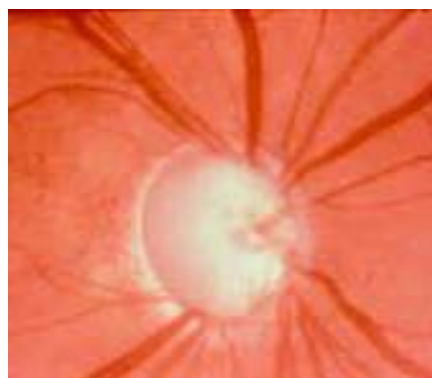


Glaucoma Must Be Diagnosed Precisely Because:

Ocular complications of Glaucoma may produce profound and irreversible loss of vision, especially when unrecognized or treated improperly. Untreated glaucoma leads to progressively diminishing vision, degeneration of the optic nerve, and blindness. If untreated, acute glaucoma results in complete and permanent blindness within 2 to 5 days. Chronic glaucoma may show no symptoms except for gradual loss of side vision over a period of years. Patients suspected of having Glaucoma should, therefore, be referred immediately for complete ophthalmologic evaluation.

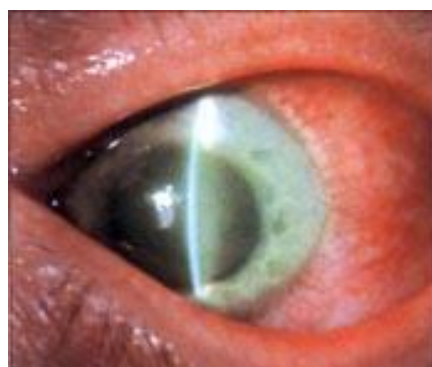Causes and Incidence

The aetiology of primary glaucoma is unknown, but predisposing factors include heredity, hyperopia, and vasomotor instability. It is estimated that 1.5% to 2% of Europeans over 40 years of age have glaucoma, and more than 12% of newly diagnosed cases of blindness are attributable to glaucoma. Blacks and those with a family history are most susceptible. Ninety percent of primary glaucoma cases are the open-angle type, which occurs most often after age 65 (Picture right - Glaucoma fundus in chronic open-angle type).



Disease Process

Increased intraocular pressure (IOP) is related to an imbalance in the production, inflow, and outflow of aqueous humour. Inflow occurs through the pupil and outflow through the meshwork at the juncture of the iris and cornea. In secondary glaucoma the meshwork becomes clogged by blood, fibrin, or inflammatory cells produced by an underlying ocular disorder (Picture right - Glaucoma).

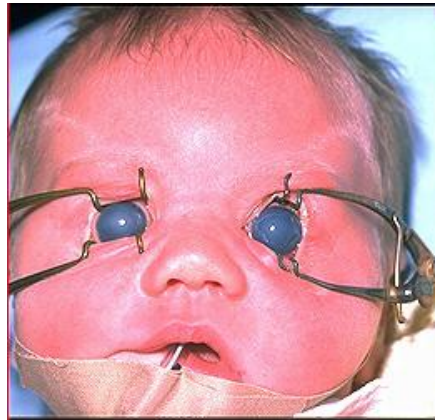


Primary **open-angle glaucoma** is marked by degenerative changes to the meshwork that block outflow.

In primary **closed-angle glaucoma**, the anterior chamber is shallow, the filtration angle is narrow, and the iris obstructs the meshwork at Schlemm's canal. Sometimes dilation of the pupil or trauma pushes the iris forward, narrowing the angle and resulting in obstruction in an acute attack.

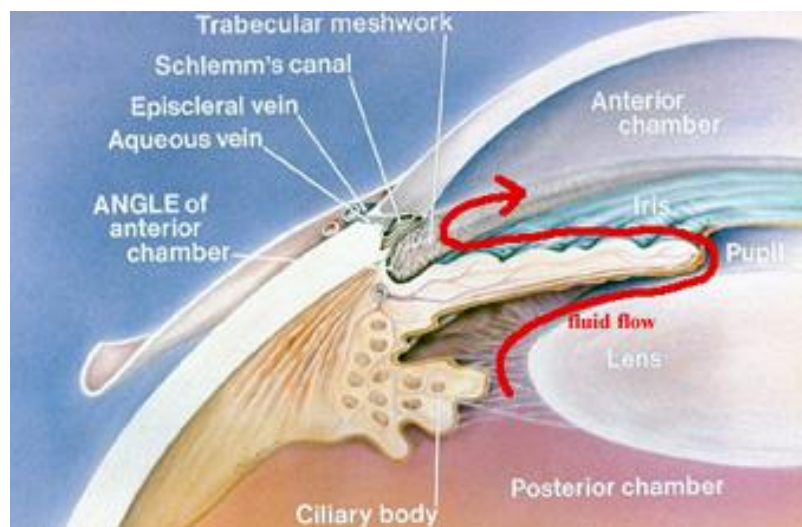
Primary or secondary glaucoma may be congenital; the condition is hereditary (primary) or is caused by foetal defects in the ocular structure or underlying congenital systemic disorders (secondary).

(Picture below - Congenital glaucoma (note the distinctive coloured hazing))

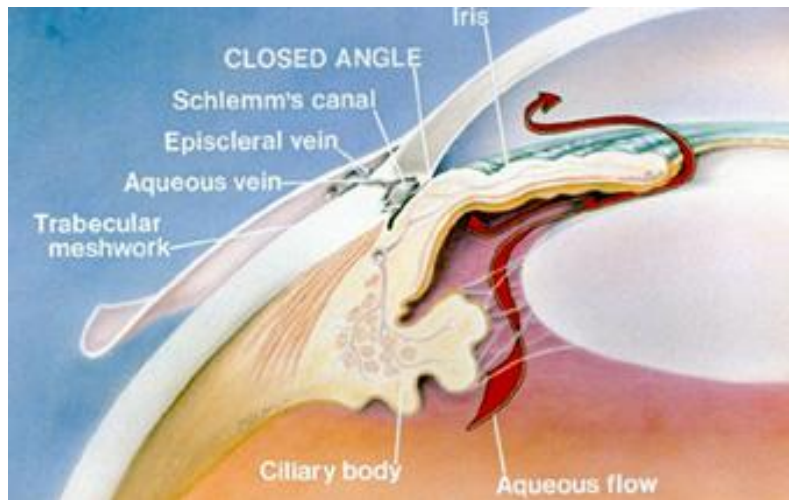


Symptoms

Open-angle glaucoma - Often asymptomatic; frequent changes in prescription for glasses; mild headaches, vague visual disturbances; halos around lights; difficulty adjusting to darkness (Picture below - Open-angle Glaucoma).



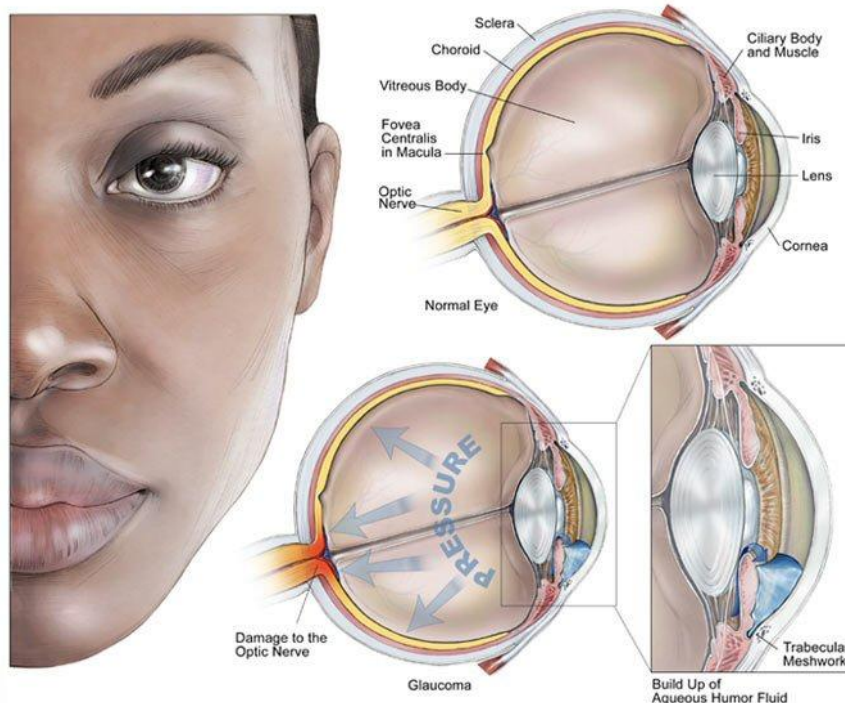
Closed-angle glaucoma - Severe pain in and around eye; tearing; coloured rainbow halos around lights; recurring episodes of blurring and impaired vision; mild dilation of pupils; hazy cornea; possible nausea and vomiting (Picture below - Closed-angle Glaucoma).



Potential Complications

Untreated glaucoma leads to progressively diminishing vision, degeneration of the optic nerve, and blindness.

Most forms of glaucoma are characterized by high intraocular pressure. Intraocular pressure is maintained at normal levels when some of the fluid produced by the eye is allowed to flow out. The fluid (aqueous humour) is produced by the ciliary body where it flows into the anterior chamber and then out through a spongy tissue at the front of the eye called the trabecular meshwork into a drainage canal. In open-angle glaucoma, fluid cannot flow effectively through the trabecular meshwork, and this causes an increase in intraocular pressure causing damage to the optic nerve and leading to vision loss (See Picture below).



How does vision alter with Glaucoma?

(Picture below - vision distorted by Glaucoma)



Diagnostic Tests

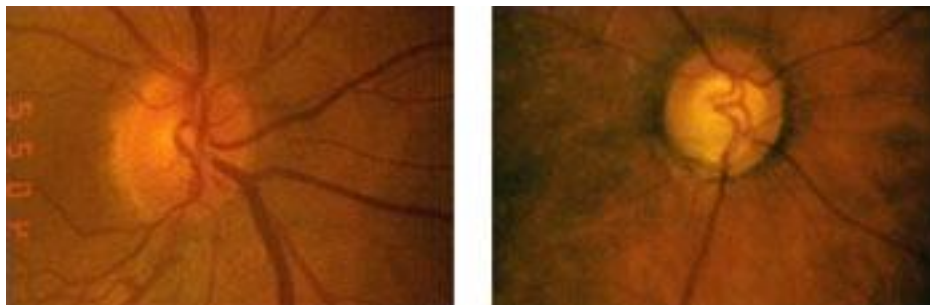
Tonometry - To measure elevation in Intra-Ocular Pressure (IOP).

Visual field studies - To detect impairment in central and peripheral visual fields.

Gonioscopy - To detect cellular debris or adhesions and differentiate open-angle from closed-angle type.

Ophthalmoscopy - To visualise optic nerve.

Pictures below - A normal optic nerve on the left has a much smaller 'cup', or empty space in the middle of the optic nerve, than in acute glaucoma on the right.



Treatments

In secondary glaucoma, treatment focuses on the underlying disease process, in conjunction with mydriasis.

Surgery - Open-angle: laser/external trabeculoplasty to improve drainage if medications fail; placement of filtering devices if trabeculoplasty fails.

Closed-angle: laser iridotomy/peripheral iridectomy to push iris back and increase angle.

Ocular implants for some complex forms of glaucoma.

Drugs - *Open-angle*: beta-adrenergic blockers and diuretics to reduce production of aqueous humour, miotics to reduce pressure, and adrenergics to increase aqueous outflow.

Closed-angle: hyperosmotic agents, carbonic anhydrase inhibitors, and miotics to reduce pressure or abort acute attack; narcotic analgesics for pain.

General - *Open-angle*: avoidance of tobacco use, fatigue, emotional upset, and ingesting large quantities of fluid; instruction in instillation of eye drops, and long-term use of medications and their side effects.

End

--()--

<http://campbellmgold.com>

27082010/1