

# CORNEAL ULCERATION

Compiled by

Campbell M Gold

(2006)

CMG Archives

<http://campbellmgold.com>

--()--

## IMPORTANT

The health information contained herein is not meant as a substitute for advice from your physician, or other health professional. The following material is intended for general interest only; and it should not be used to diagnose, treat, or cure any condition whatever. If you are concerned about any health issue, symptom, or other indication, you should consult your regular physician, or other health professional. Consequently, the Author cannot accept responsibility for any individual who misuses the information contained in this material. Thus, the reader is solely responsible for all of the health information contained herein. However, every effort is made to ensure that the information in this material is accurate; but, the Author is not liable for any errors in content or presentation, which may appear herein.

--()--

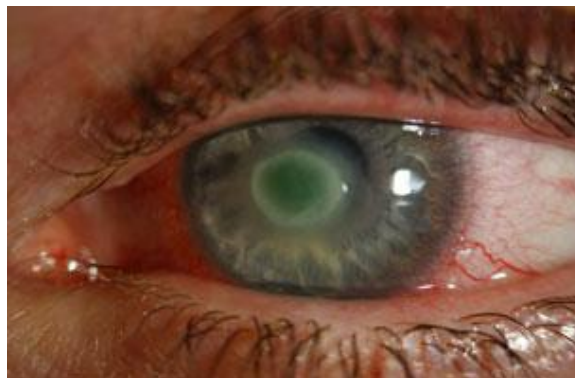
### Introduction

In consequence of the cornea being grazed or scratched, bacteria, viruses, and fungal infections of the cornea can flourish.

Such injuries can occur from dirt or grit in the eye, or from a contact lens injury. Therefore, referral must be made with history of 'grittiness' in one eye with vision distortion in consequence of constant/persistent watering. Moreover, an ulcer must be immediately treated since it can enlarge and effect permanent damage.

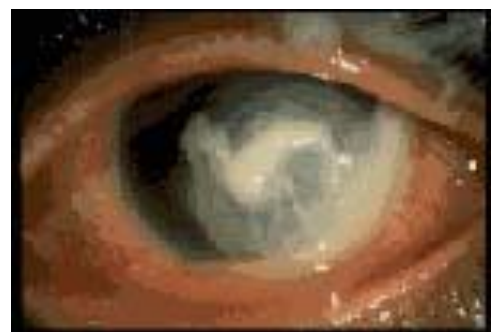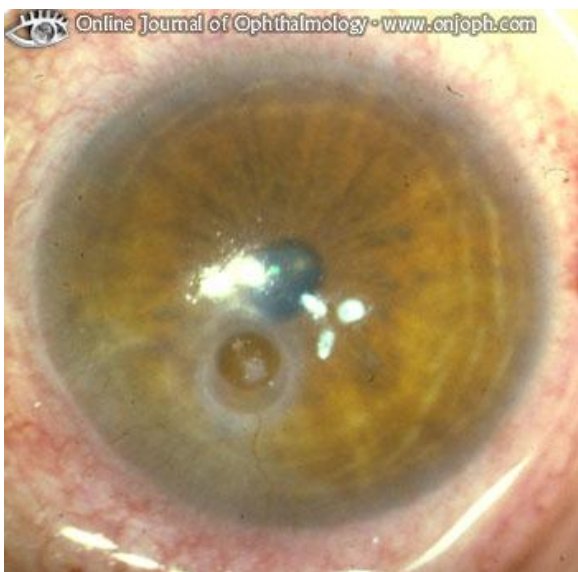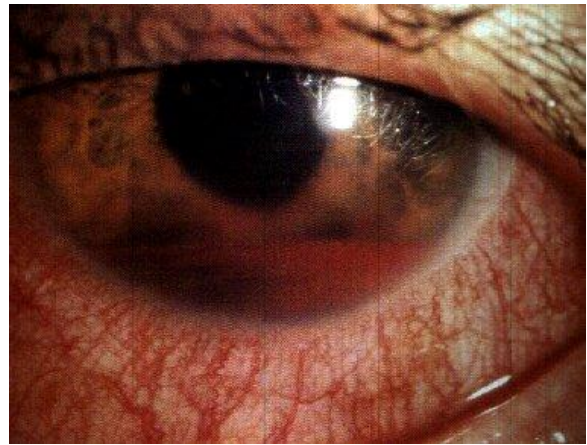
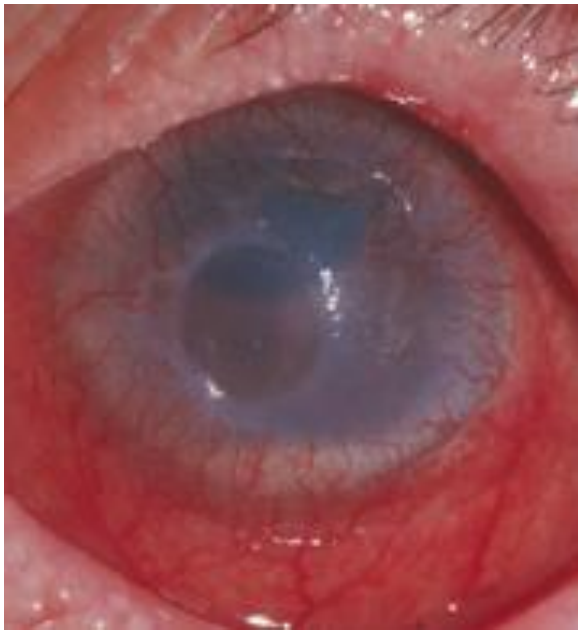
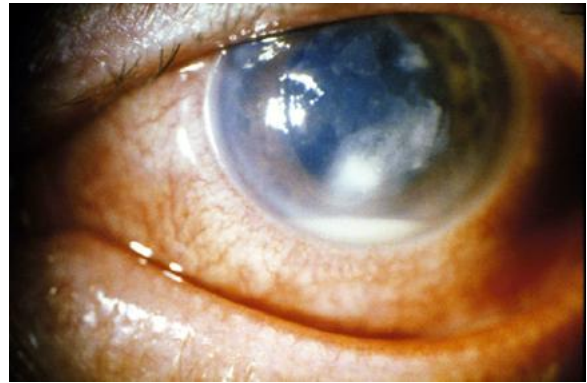
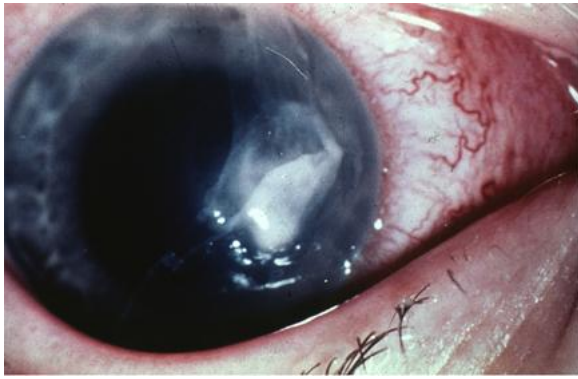
The following examples show corneal compromise

#### 1) Corneal Ulcer

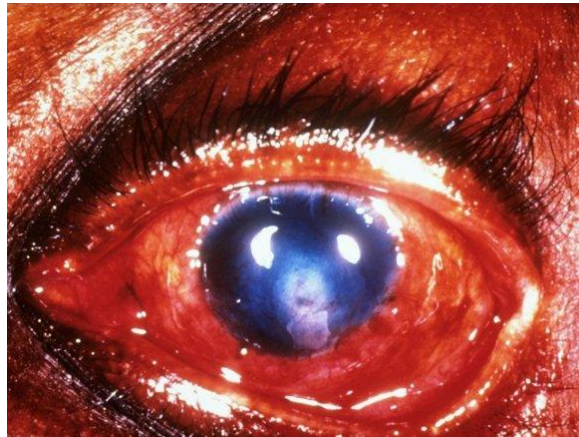


--()--

## 2) Bacterial Corneal Ulcer

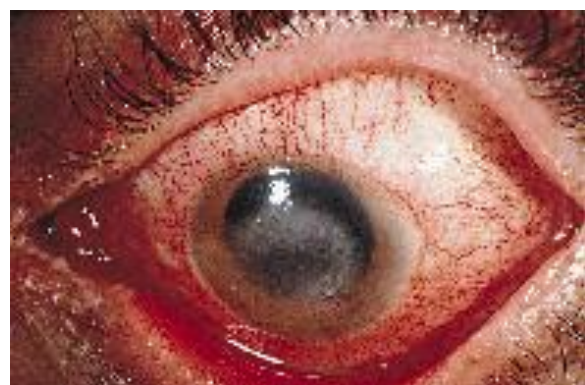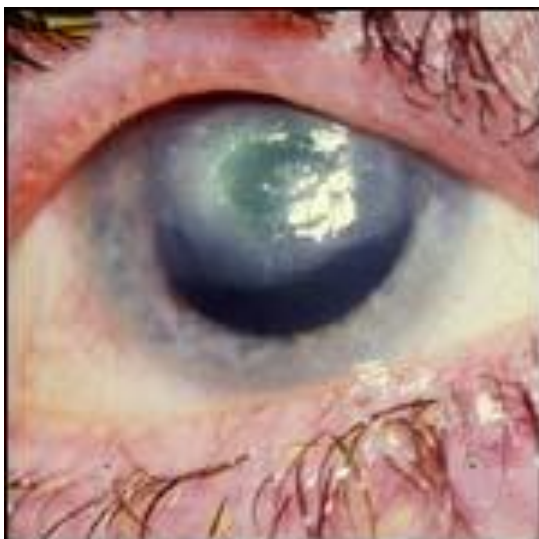
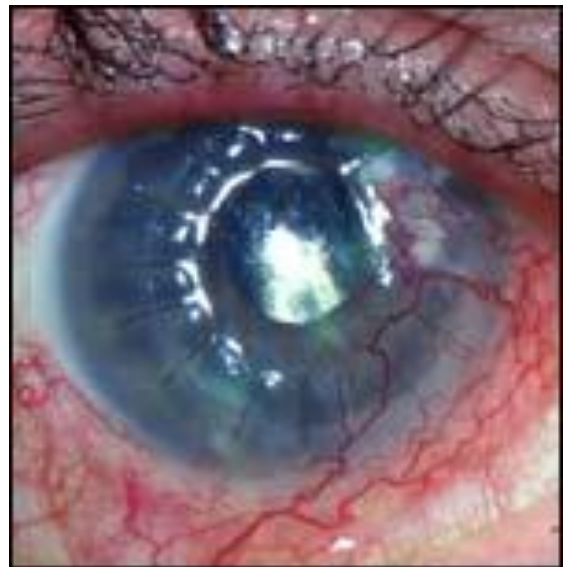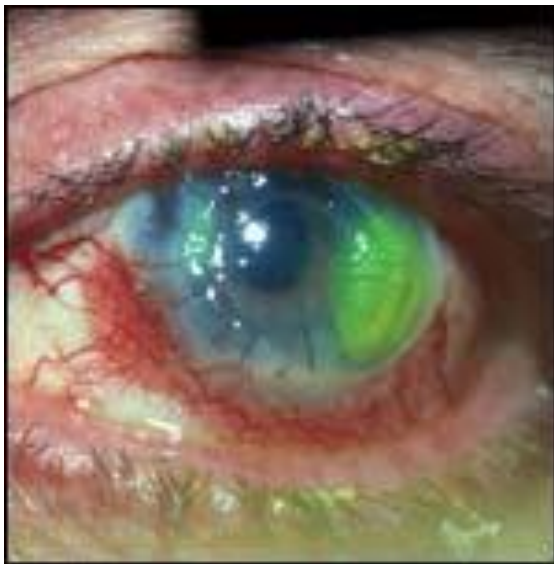


**2) Fungal Corneal Ulcer**



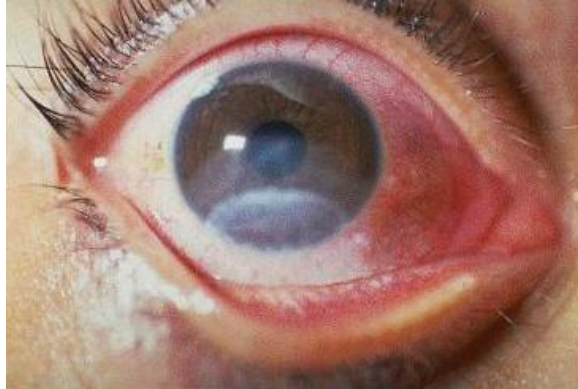--()--

**3) Virus Corneal Ulcer**



--()--

#### 4) Corneal Ulcer



End

--()--

<http://campbellmgold.com>

26082010