

JFK
AUTOPSY
PHOTOGRAPHS

Compiled by
Campbell M Gold



John F Kennedy
(29 May 1917 - 22 November 1963),

(2010)

Warning
This material contains disturbing images.

This material has been compiled from various unverified sources
and is presented, as received by the compiler, for academic interest only

--()--

Introduction

Please Note:

The following material is visually disturbing and does not reflect, in any way, the Compiler's personal opinion or esoteric viewpoint. It is presented, as is, for academic interest only

John F. Kennedy, the thirty-fifth President of the United States, was assassinated at 12:30 p.m. Central Standard Time (18:30 UTC), Friday, 22 November 1963, on Dealey Plaza in Dallas, Texas. He was fatally shot while riding with his wife, Jacqueline, in an open Presidential limousine.



Above - President John F Kennedy with his wife, Jacqueline, and Texas Governor John Connally with his wife, in the presidential limousine, minutes before the assassination

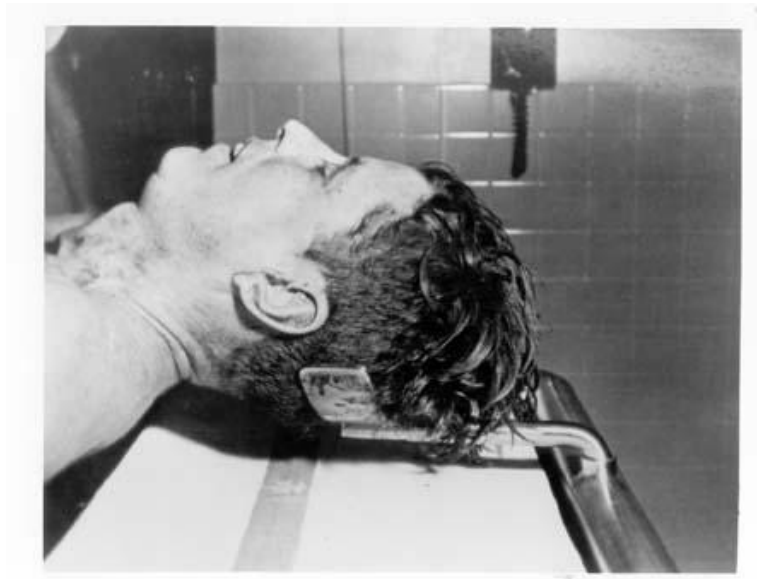After the shooting, Kennedy was taken to Parkland Hospital, Dallas, where attempts to keep him alive failed. Later, Kennedy's body was taken to Washington DC, and an autopsy was performed, on 22 November 1963 (the day of JFK's assassination), at the then Bethesda Naval Hospital in Bethesda, Maryland. It began at about 8 p.m. and ended about midnight (EST).

There has been a lot of speculation regarding the JFK Assassination, and numerous conspiracy theories abound. The following material contains a collection of photographs which are purported to be from JFK's autopsy; however, the "official" autopsy photographs have never been published and continue to be under seal at the National Archives.

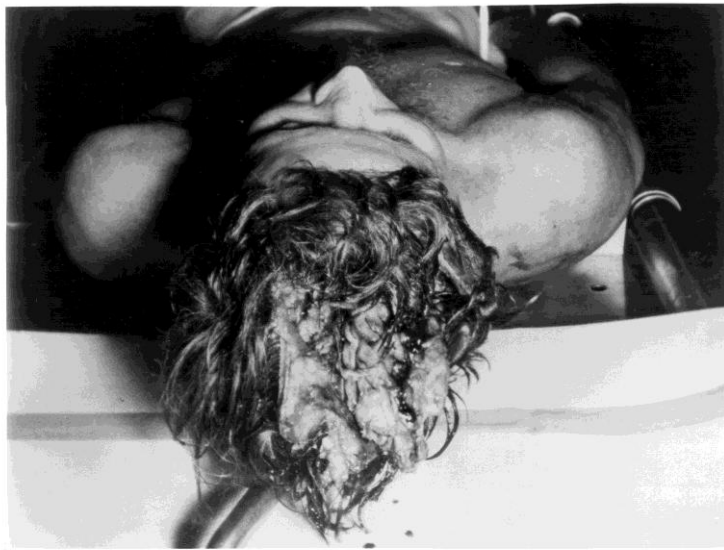--()-

Photographs

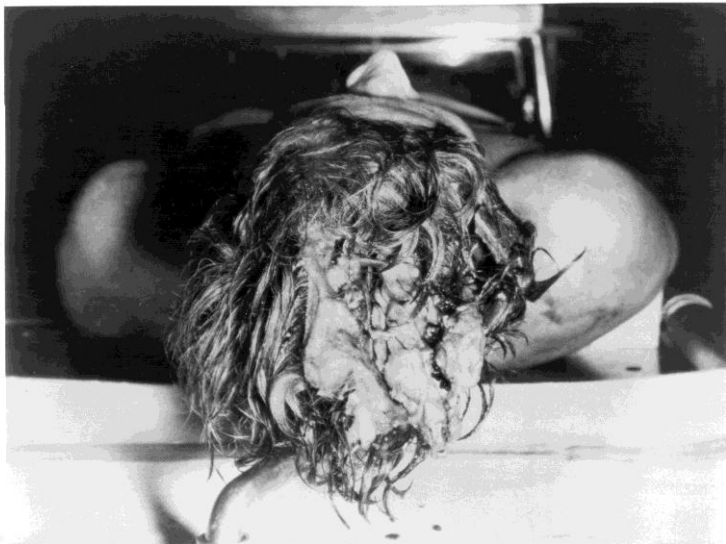Head Trauma



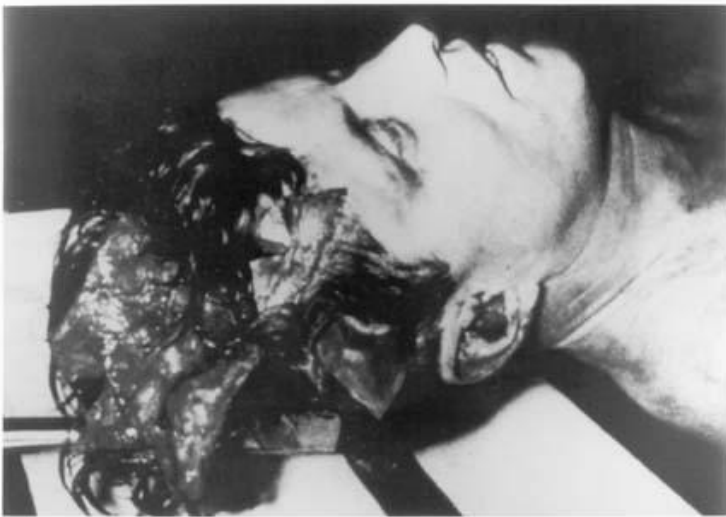Above - Undamaged Side of JFK's Head



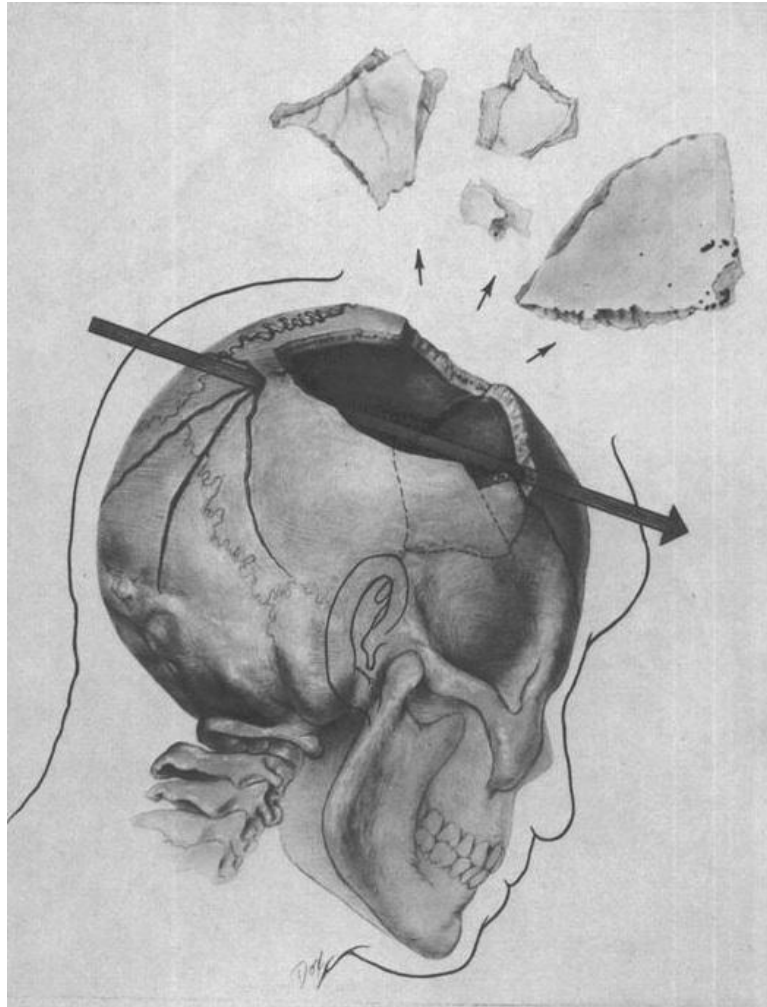
Damage to the top and back of JFK's head.
Blood and brain-matter are visible.



Above - Damage to the top and back of JFK's head.
Blood and brain-matter are visible.



Above - Photograph of JFK's head taken during the autopsy.
Blood and brain-matter are visible.



Above - Diagram showing the possible trajectory of the missile through JFK's skull.
The skull fragments not drawn to scale. Made by medical illustrator Ida G. Dox

--()-

X-Rays

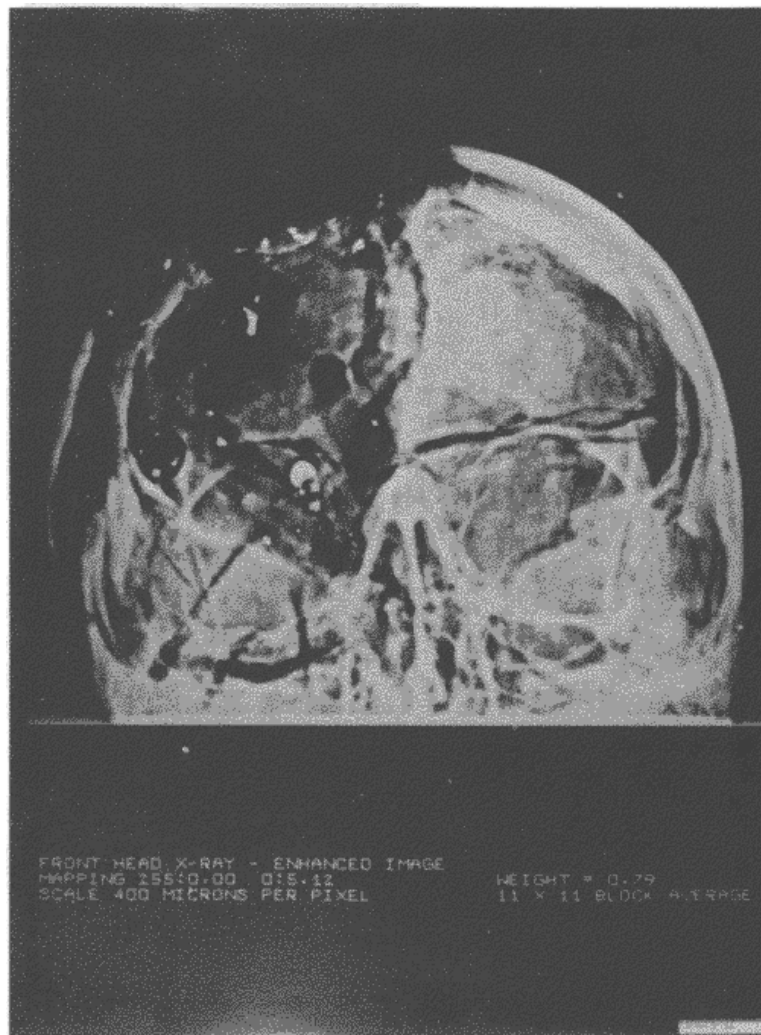
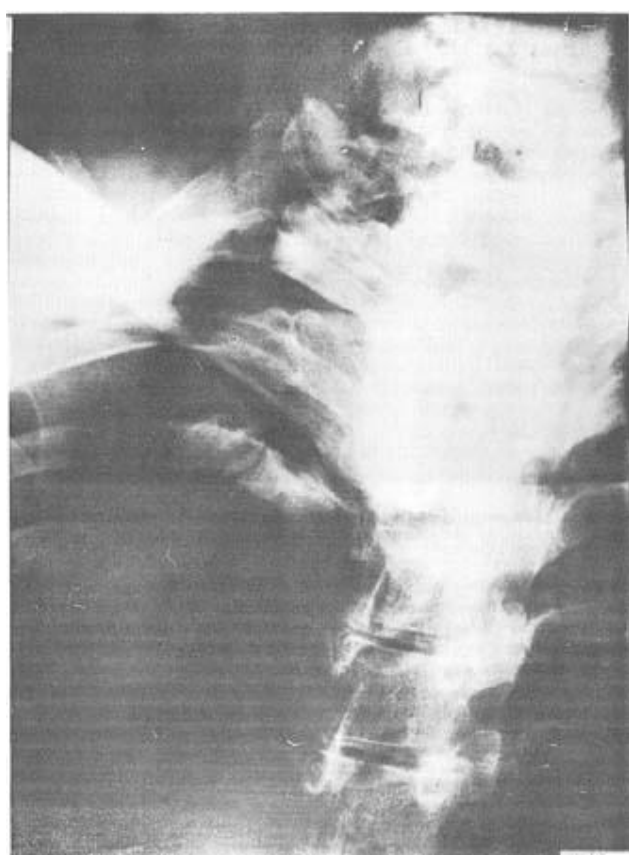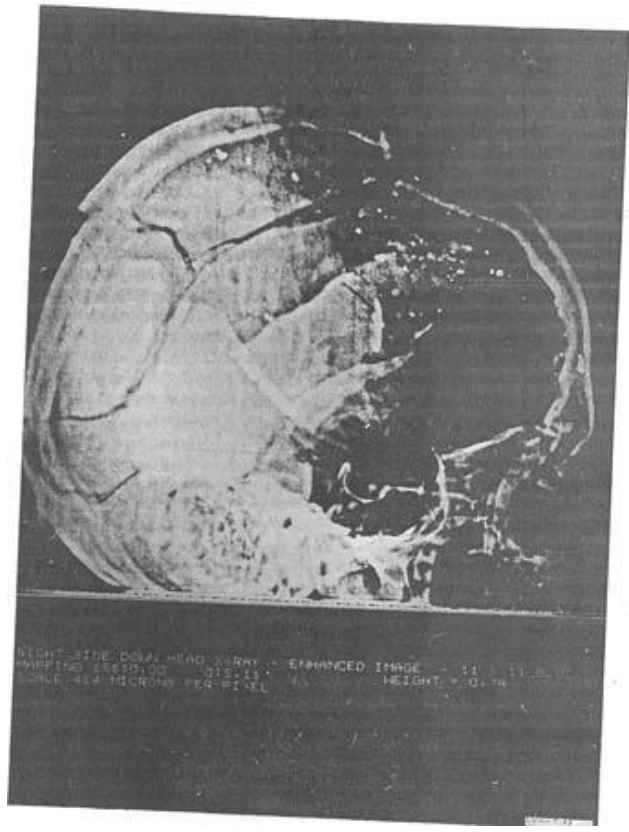
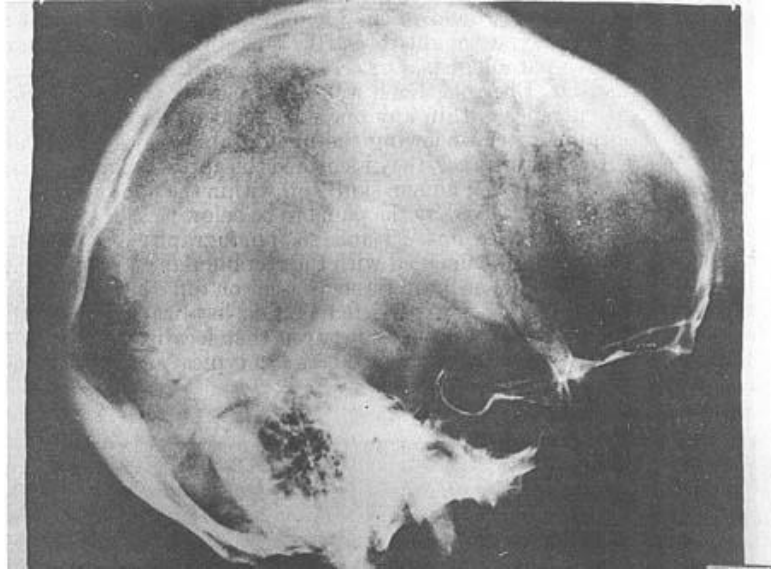


FIGURE 19.—Photograph of a computer-assisted image enhancement of anterior-posterior X-ray of the skull (autopsy X-ray No. 1).

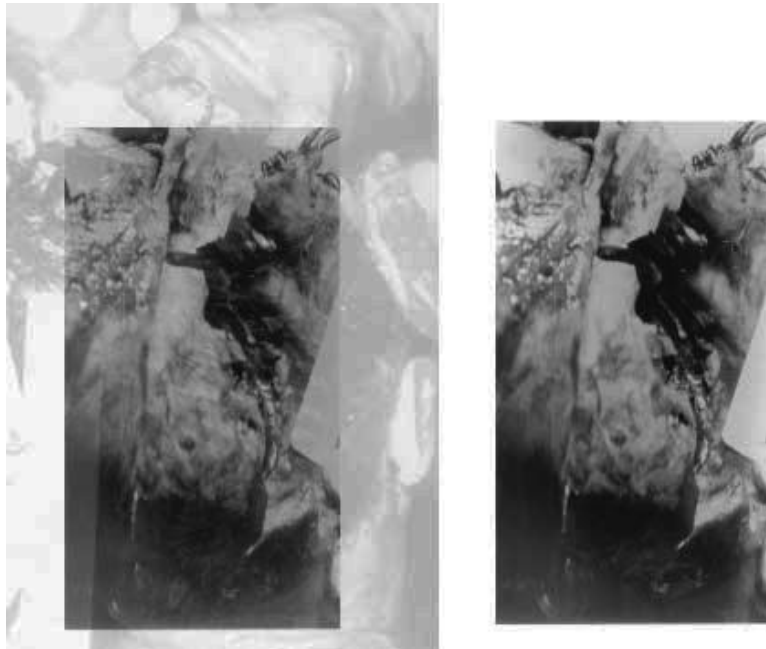Above - X-ray - front view, of JFK's skull



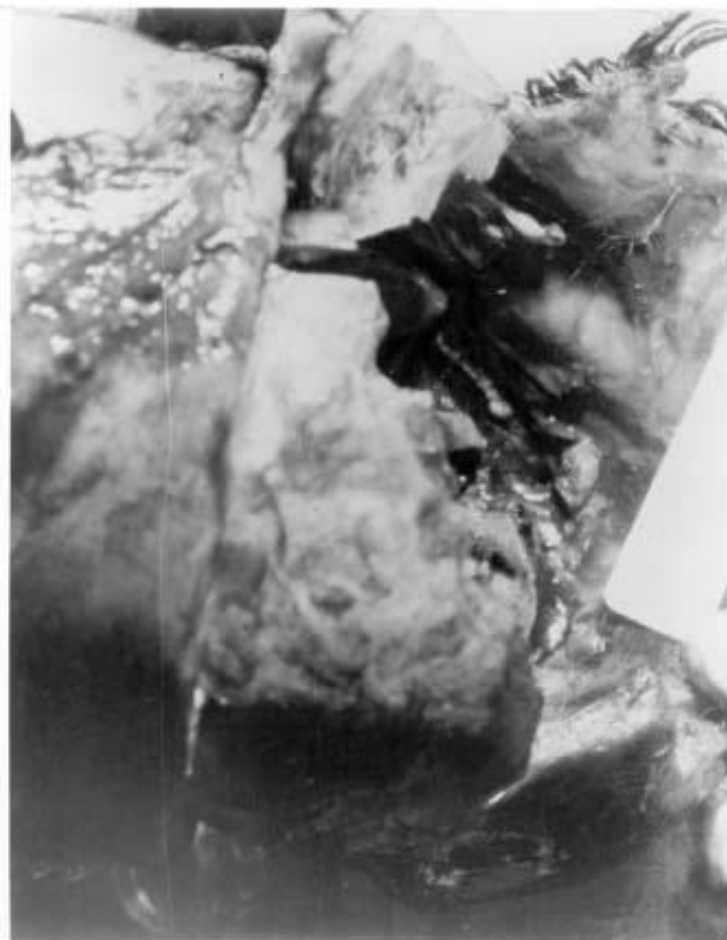

--()--

Large Defect



Above - Large Defect



Above - Detail of Large Defect

The Head Shot



Above - Frame from the Zapruder Film.
"The Head Shot"

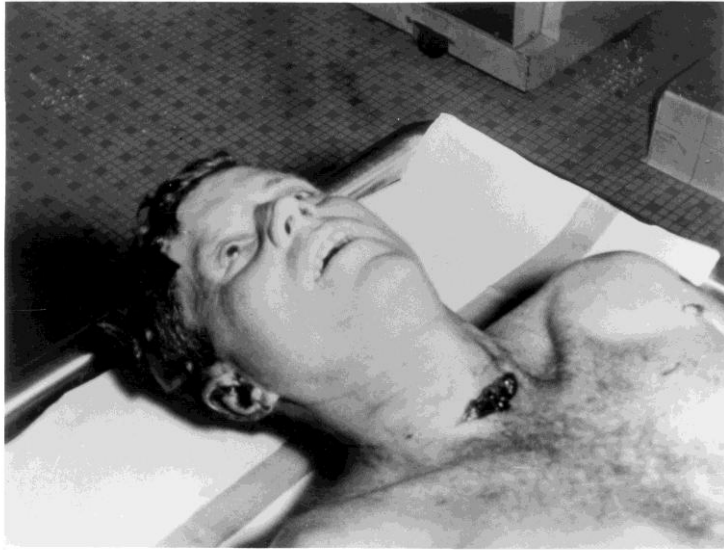Head-wound Testimony

"The headwound was difficult to see when he was laying on the back of his head. However, afterwards when they moved his face towards the left, one could see the large, right rear parietal, occipital, blasted out hole, the size of my fist, which is 2 and a half inches in diameter. The brain, cerebral portion had been flurred out and also there was the cerebellum hanging out from that wound. It was clearly an exit wound from the right rear, behind the ear. A right occipital area hole, the size of my fist." (Dr. Charles Crenshaw, Surgeon, Parkland Hospital)

"We wrapped him up... and I saw his whole head... There was no hair back there... It was blown away. Some of his head was blown away and his brains were fallen down on the stretcher." (Doris Nelson, Emergency-Room Nurse, Parkland Hospital)

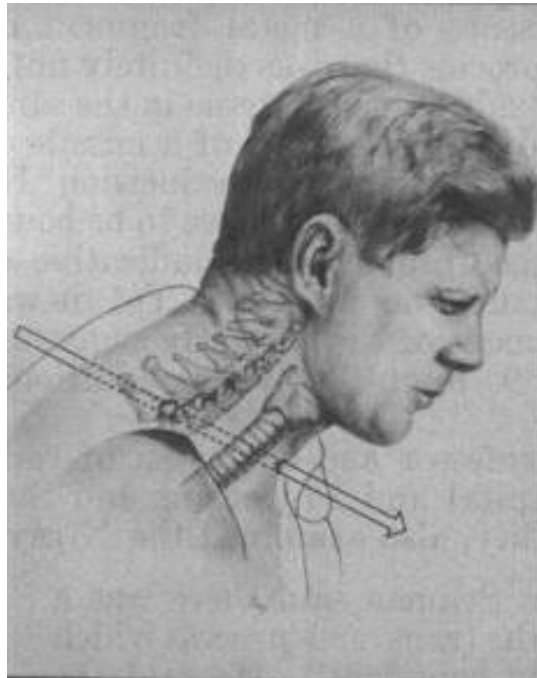
--()--

Throat Wound



Above - Wound in JFK's Throat.
"The Stare of Death"

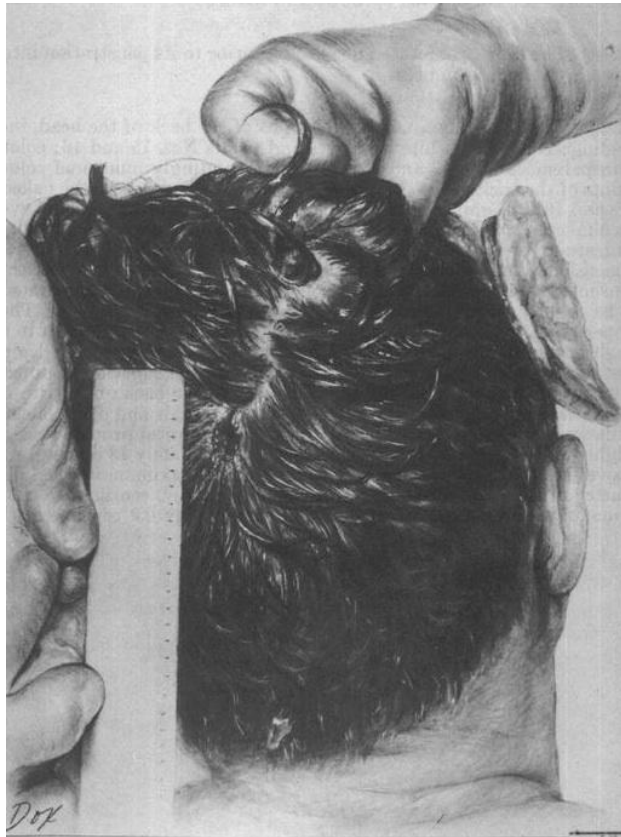
"As I was cutting off his trousers around his waist, I was on the right side, there was a small entrance wound, about 4 to 8 millimeters in size. Clearly an entrance wound in the lower third of the neck, below the adam's apple in the throat. Dr. Carrico had put in the tracheotomy tube to try to assist him with breathing." (Dr. Charles Crenshaw, Surgeon, Parkland Hospital)



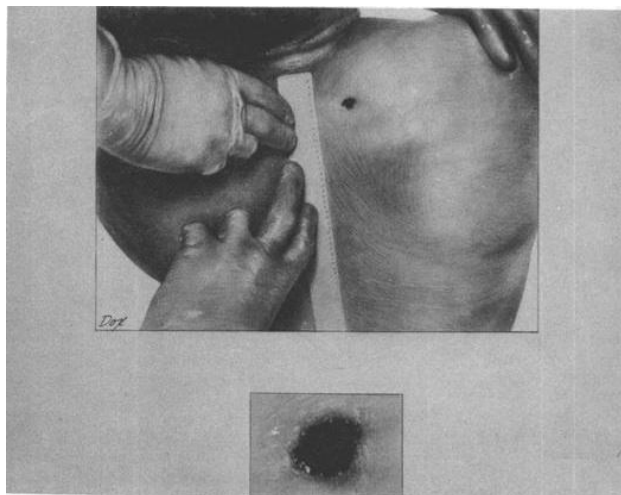
Above - Medical drawing of a cross-section of President Kennedy's neck and chest, showing the possible trajectory of the projectile from back to throat

--()--

Drawings



Above - Drawing depicting the posterior head wound of U.S. President John F. Kennedy.
The hand at the top is holding a portion of his scalp in place.
Made by medical illustrator Ida G. Dox from an autopsy photograph



Above - Drawing of the posterior thorax of John F. Kennedy,
revealing the general location and appearance of the entrance wound in the upper back.
This drawing was made by medical illustrator Ida G. Dox from an autopsy photograph,

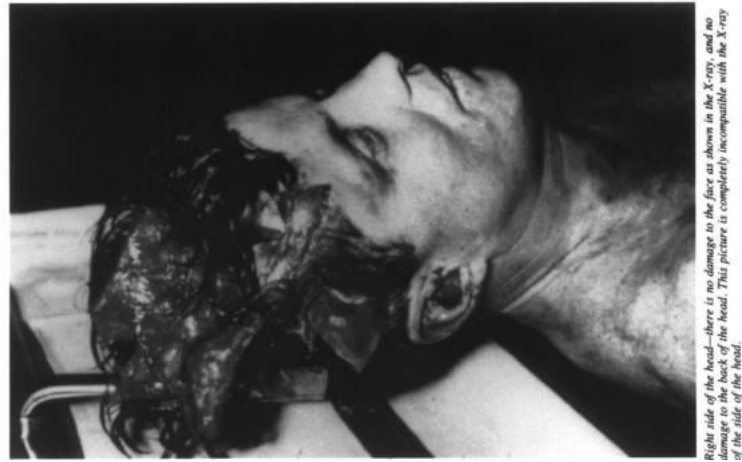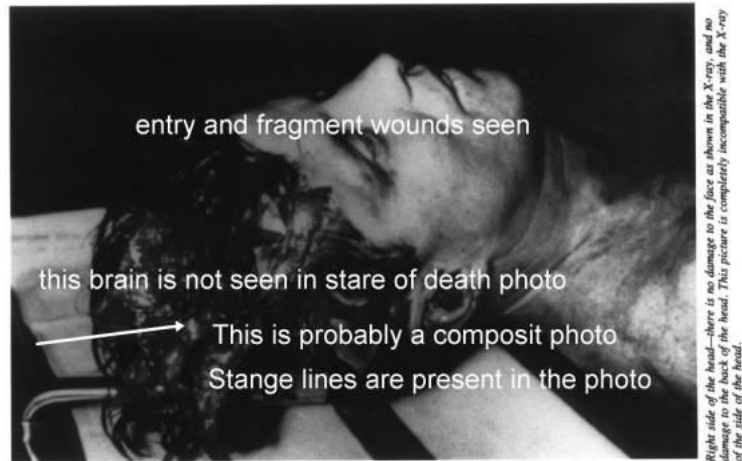
--()--

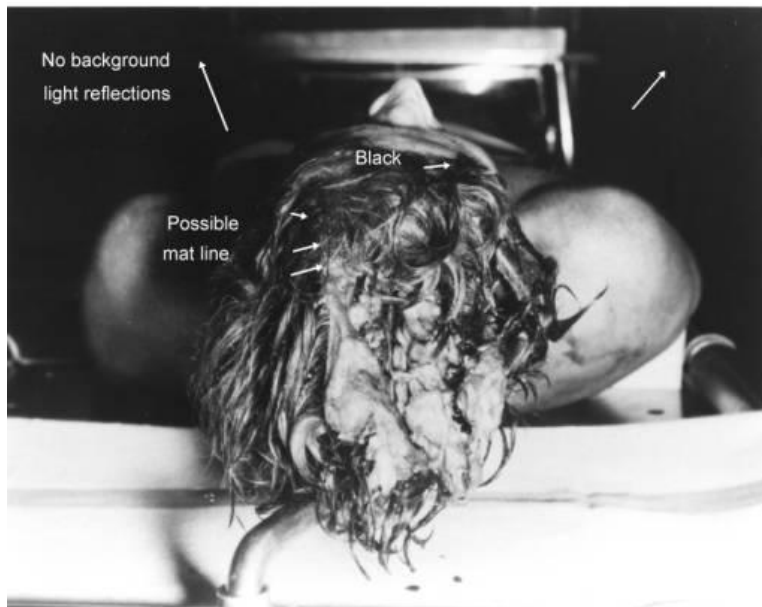
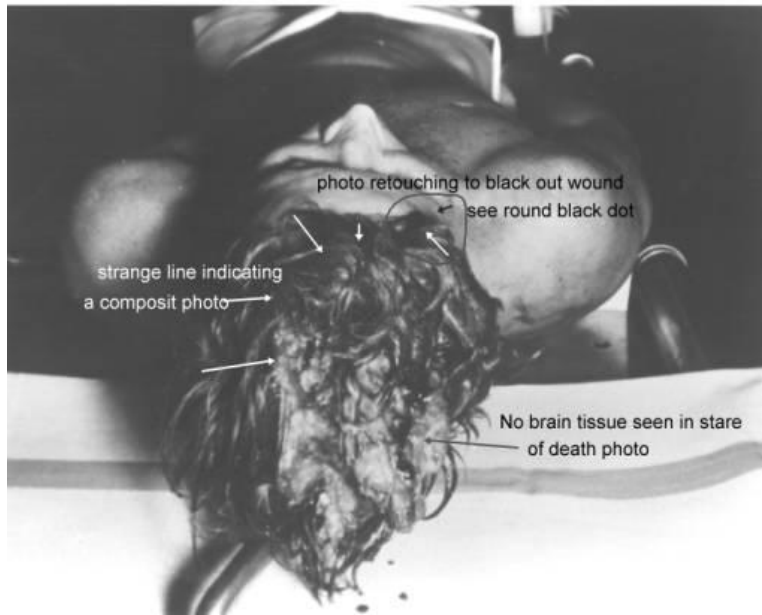
Unverified/Cover-up/Tampered Photographs - Questions... Conspiracy?

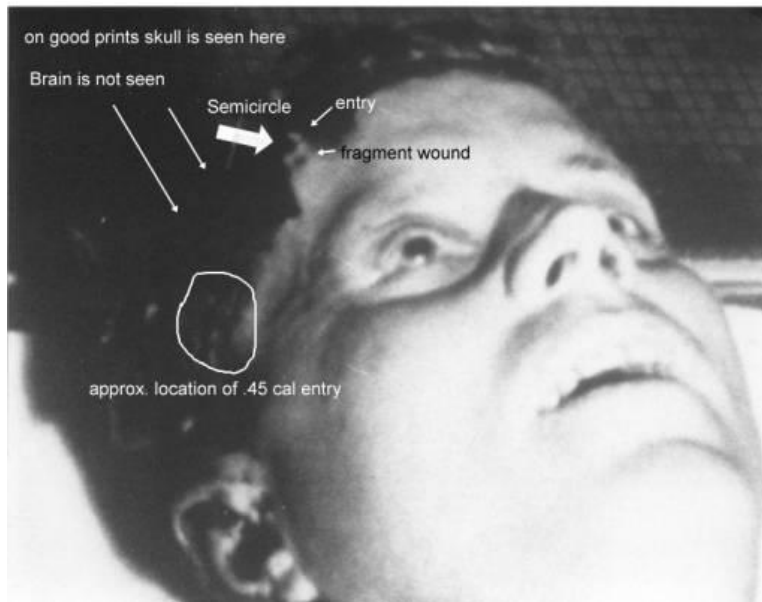
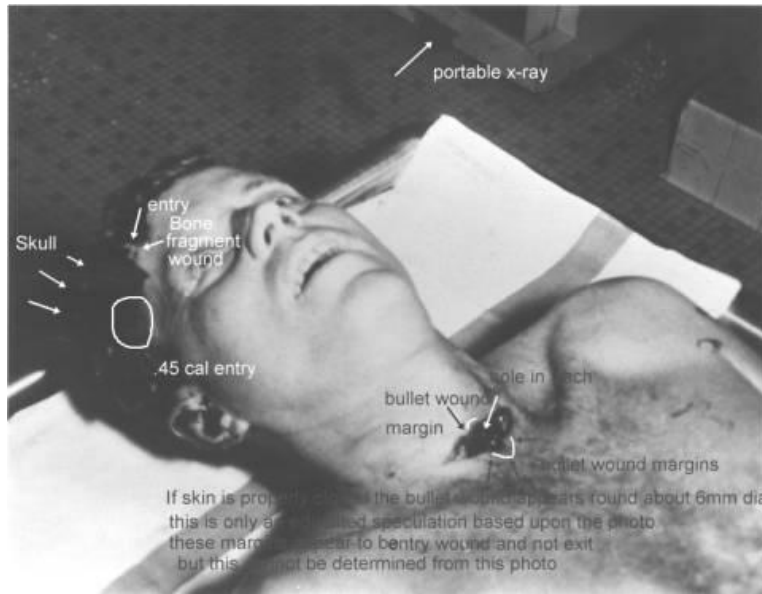
Photographs have been annotated by original sources to highlight areas of concern.

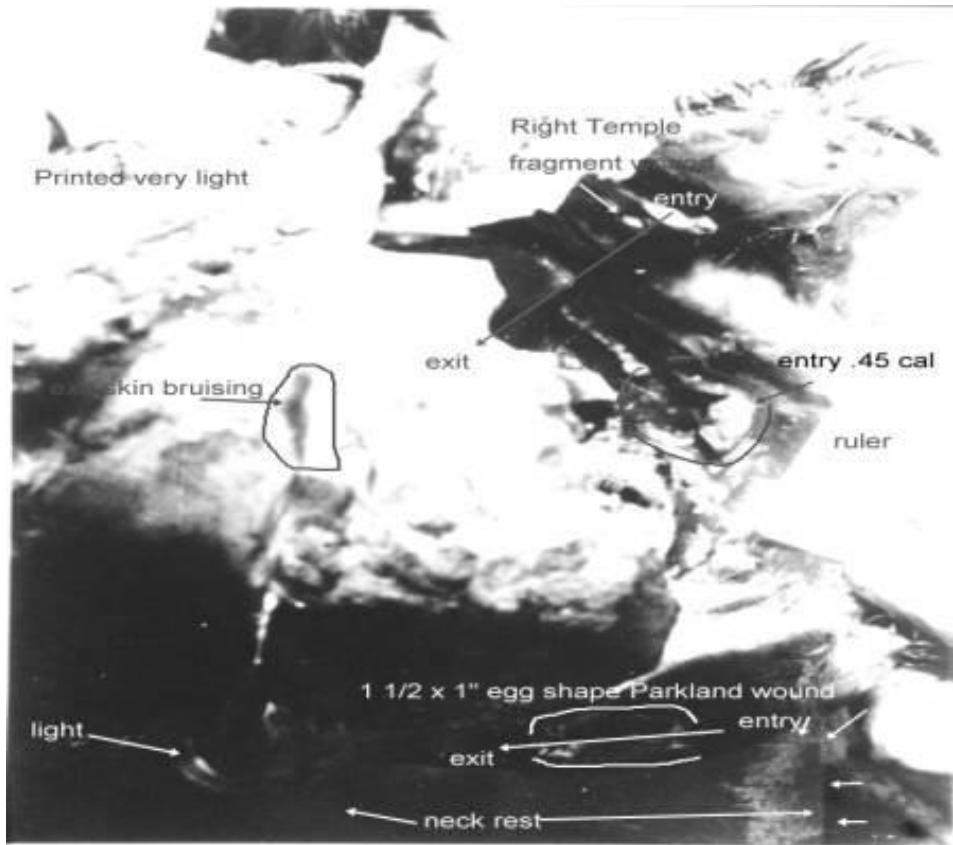
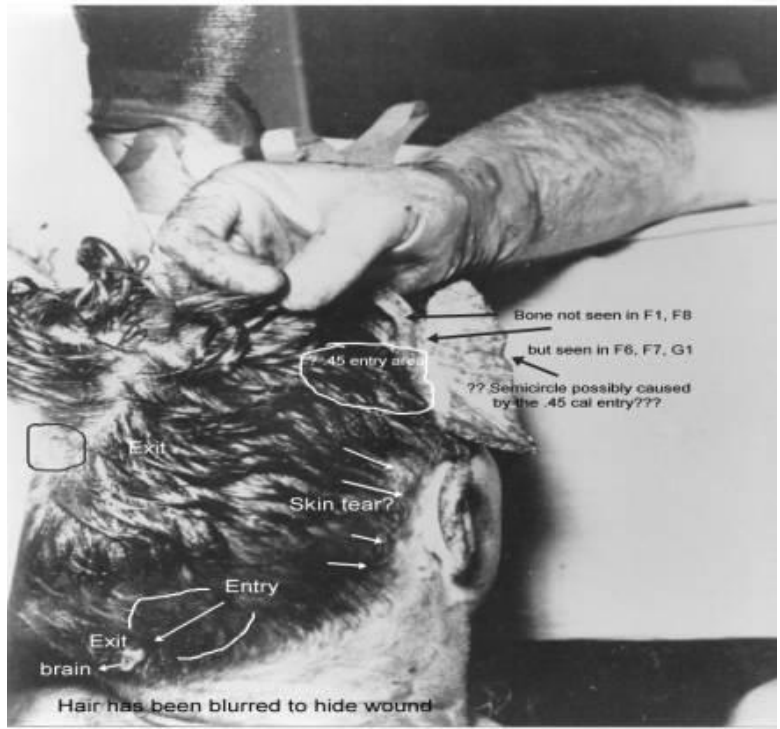The following photographs are present as they were received by the compiler.

Head Trauma






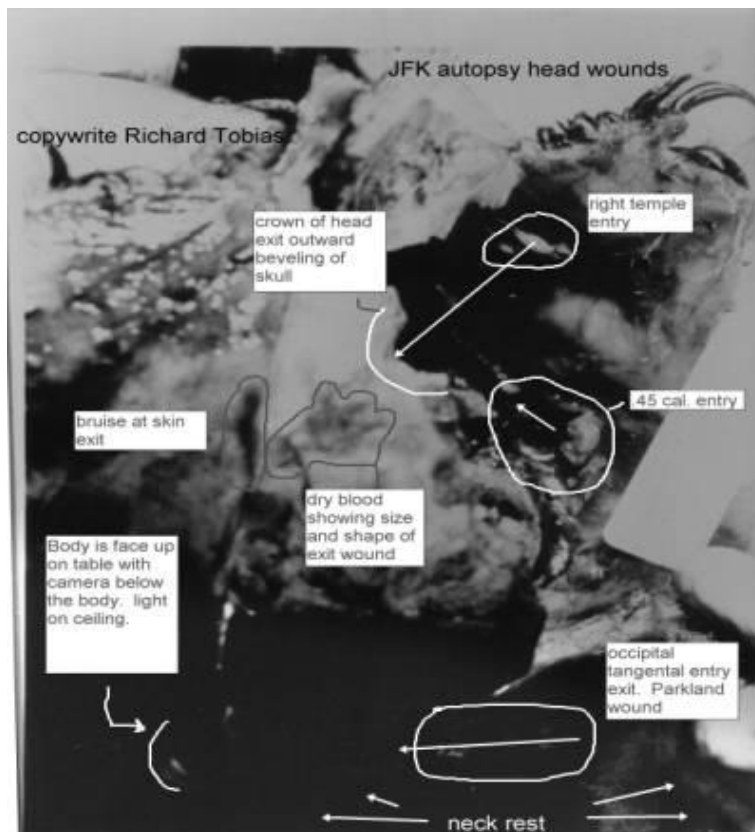




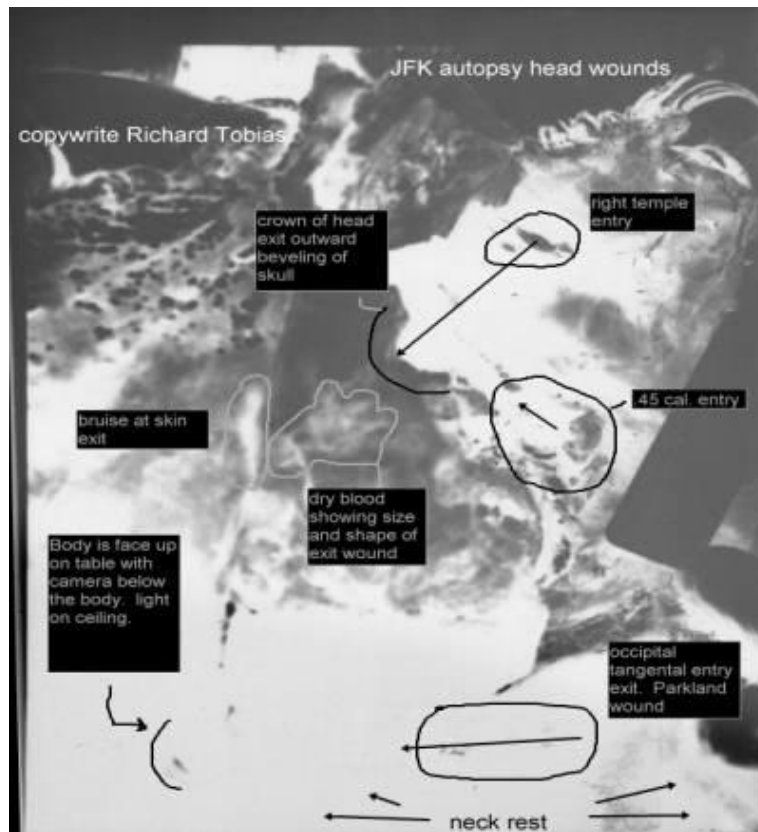
Above - Normal



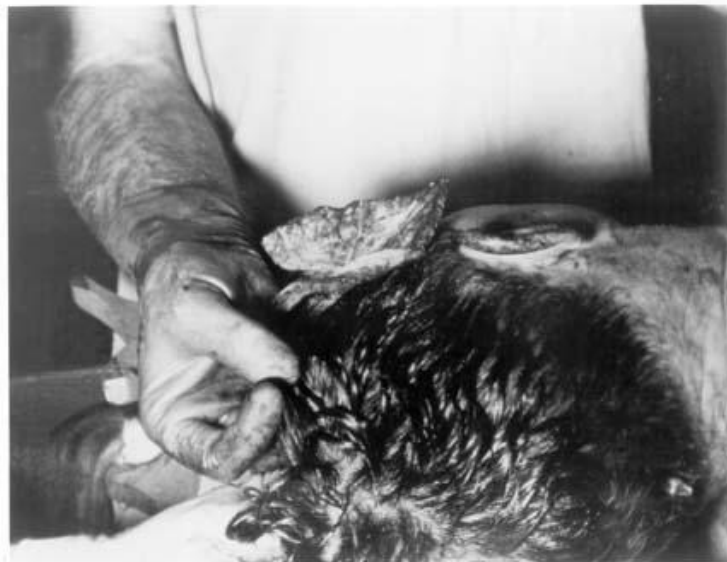Above - Negative



Above - Normal



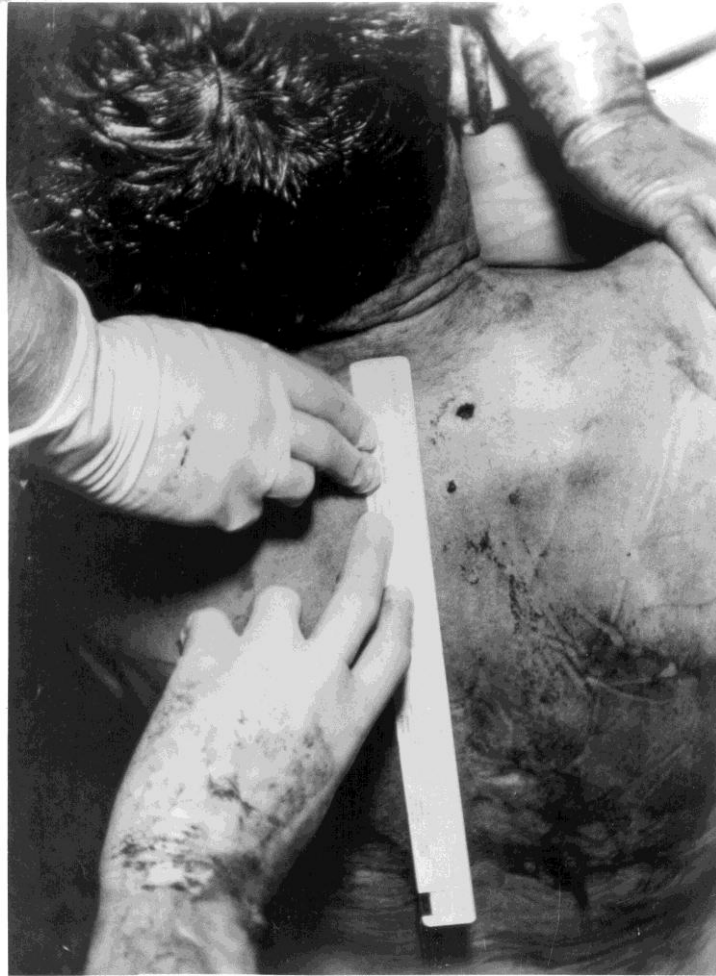Above - Negative

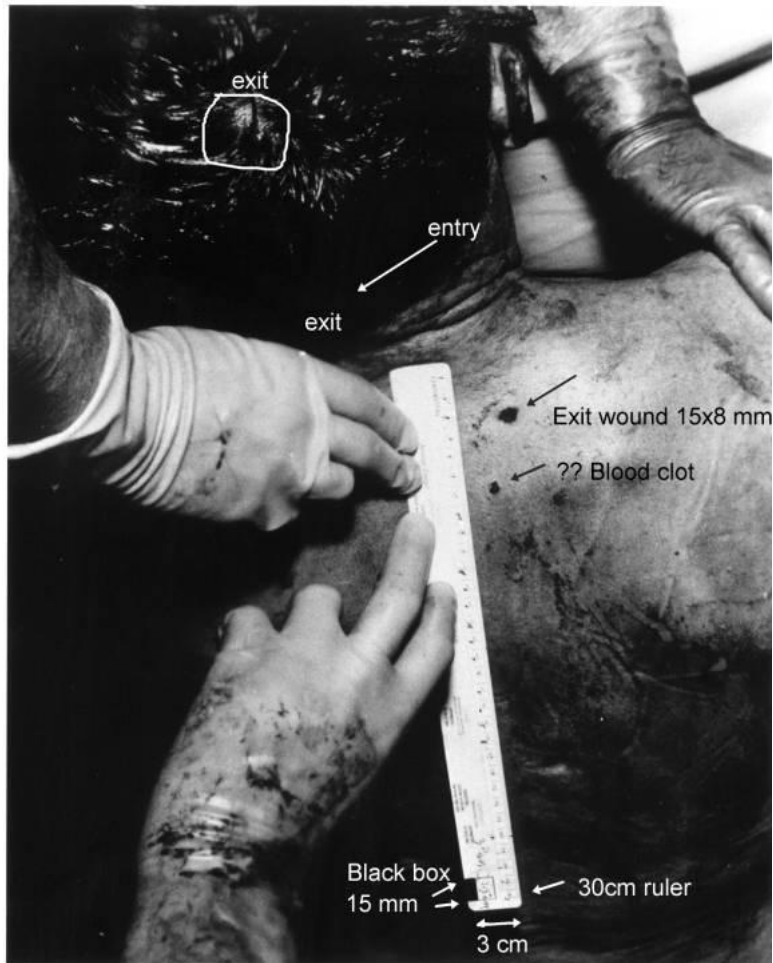


Above - Note the similarity of the head to the head in the drawings, made by made by medical illustrator Ida G. Dox

--()--

Back Wound





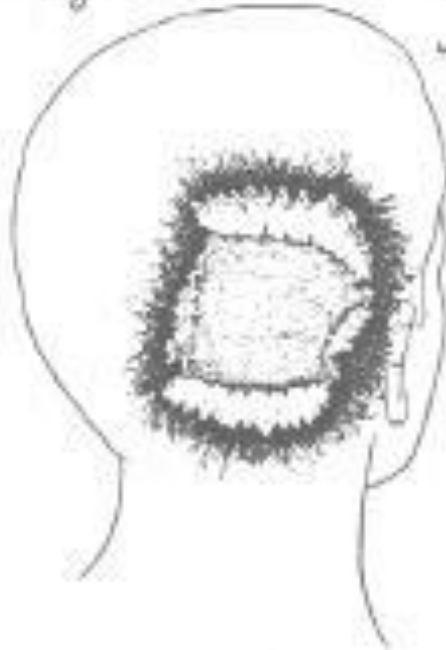
Note the similarity of the head to the head in the drawings,
made by made by medical illustrator Ida G. Dox

--()--

Some Miscellaneous Material of Possible Interest

Read, the drawing below is an exact copy, in regard to location and dimensions, of the drawing I made for Josiah Thompson in ~~1978~~ 1966.

January 29, 1994



Best wishes,
R. N. McClelland

A pictorial representation of President Kennedy's head wound as described by Dr. Robert N. McClelland of Parkland Hospital.

David Naro
3779 Knight Rd.
Memphis, TN 38118

Dr. Cyril H. Wacht, M.D.
Dept. of Pathology
St. Francis Central Hospital
1200 Center E. Ave.
Pittsburgh, PA 15219

January 07, 1994

Dr. Wacht:

Confirming our telephone conversation of 01-07-94, I spoke with Dr. Kemp Clark on Wednesday, January 05, 1994. I telephoned Dr. Clark at his office at Parkland Hospital in Dallas to ask some questions regarding the assassination of President John F. Kennedy.

I asked Dr. Clark what the President's head looked like. Dr. Clark said, "The back of the President's head was blown out."

I asked Dr. Clark if the wound in the back of the President's head was an exit or an entry wound. Dr. Clark's response was, "In my opinion the wound was an exit wound."

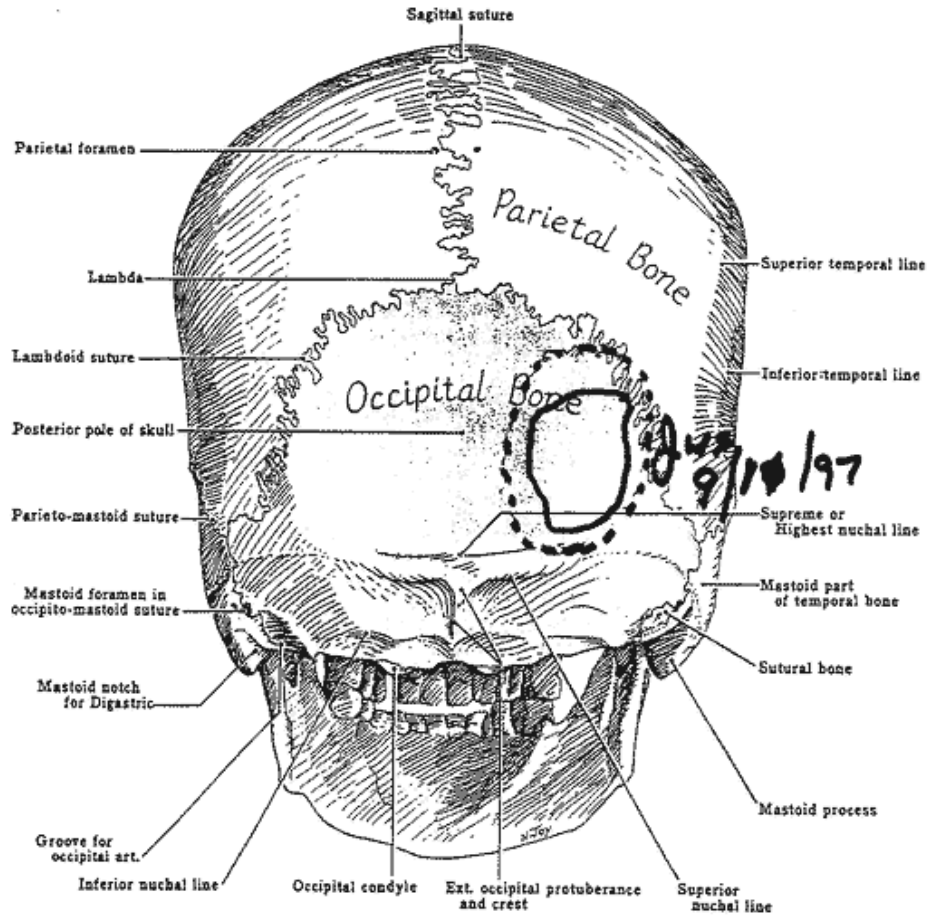
As we discussed, I am willing to testify regarding my telephone conversation with Dr. Clark.

Yours truly,



David Naro

--()--



7-9 SKULL FROM BEHIND (NORMA OCCIPITALIS)

Observe:

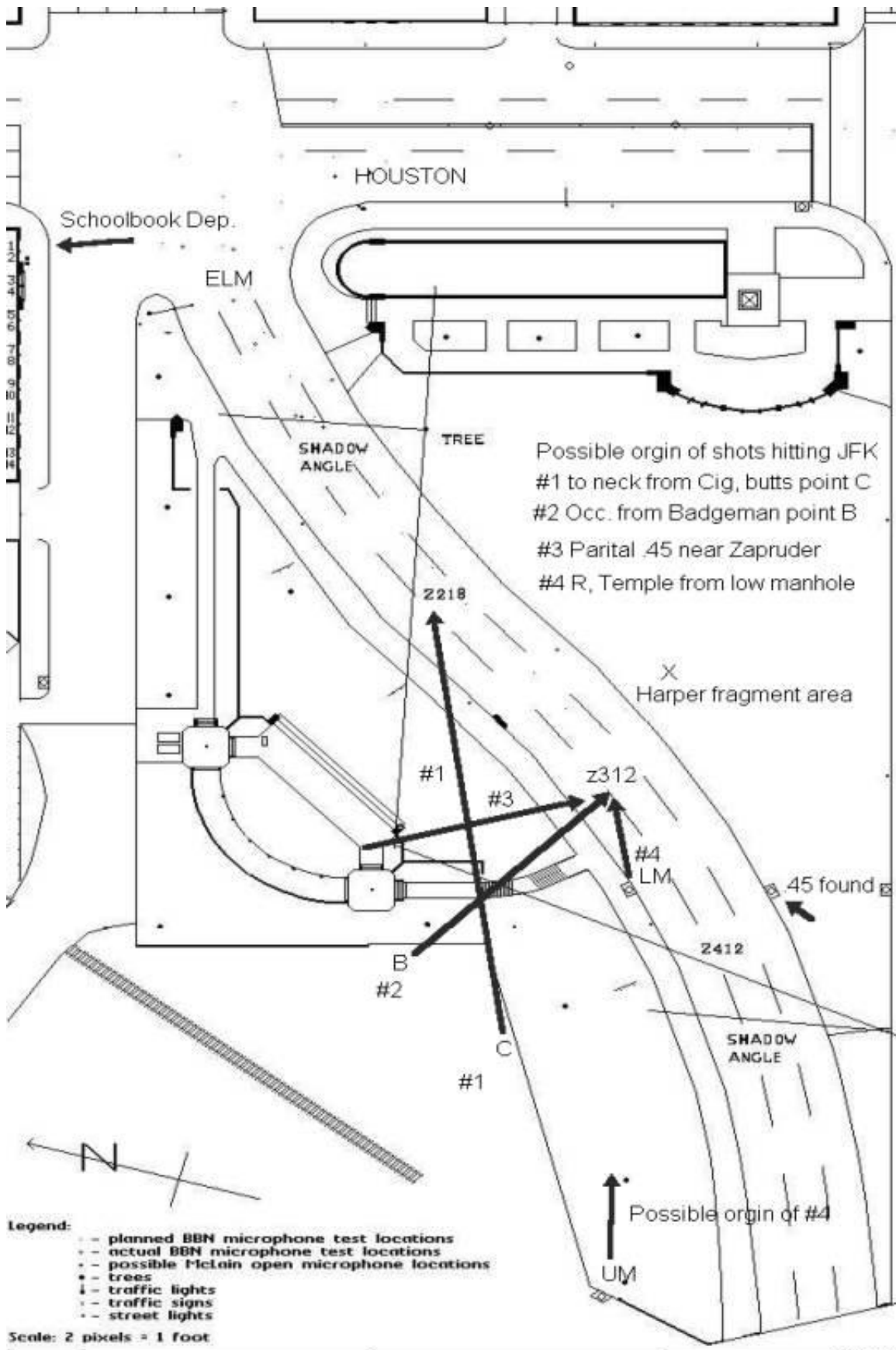
1. The outline is horseshoe-shaped from the tip of one mastoid process over the vertex to the tip of the other.
2. At the base of the skull, the outline is nearly straight from one mastoid process to the other, except where the occipital condyles project downward. On each side, it crosses two grooves (for the origin of the posterior belly of Digastric laterally, and for the occipital artery medially). Between the condyles is the foramen magnum.
3. The surface is convex. Near the center is the lambda. From it a triradiate suture runs: the sagittal (interparietal) upward in the median plane, and the lambdoid (parietooccipital) inferolaterally to the blunt postero-inferior angles of the parietal bones where it bifurcates.
4. On each side are two inconstant foramina for emissary veins and meningeal arteries: parietal and mastoid foramina.
5. Midway between lambda and foramen magnum is the external occipital protuberance or inion. From it the superior nuchal line curves laterally and crosses the lateral aspect of the mastoid, dividing it into a smooth upper and a rough lower part.
6. The surface below the superior nuchal line is the nuchal plane.

MD 188 001540 -

--()--

Alternative Possible Shot Origins

Other theories suggest that the shots originated from locales other than the Schoolbook Depository.



End

--()--

<http://campbellmgold.com>

15122010