

ANIMAL MUTILATION

BY

ALIENS

Compiled by

Campbell M Gold

(2001)

--()--

Warning

This material Contains Graphic Photos of Mutilated Animals

--()--

Introduction

Since the 1960's, there have been thousands of cases of animals which have been mysteriously mutilated. Moreover, in such cases, there is often no sign of a struggle, and no blood or tracks in the surrounding area. Further, it is not unusual for sightings of black helicopters and/or ufos in the vicinity of the mutilation. The official position, that these cases are predation by coyotes and wolves, makes no sense and is not supported by the evidence. The wounds are made with surgical precision and there is often evidence of high temperatures being used. There are two schools of thought surrounding this mystery, one saying it is being done by aliens and the other saying it is the military. As we will see there is evidence supporting both.



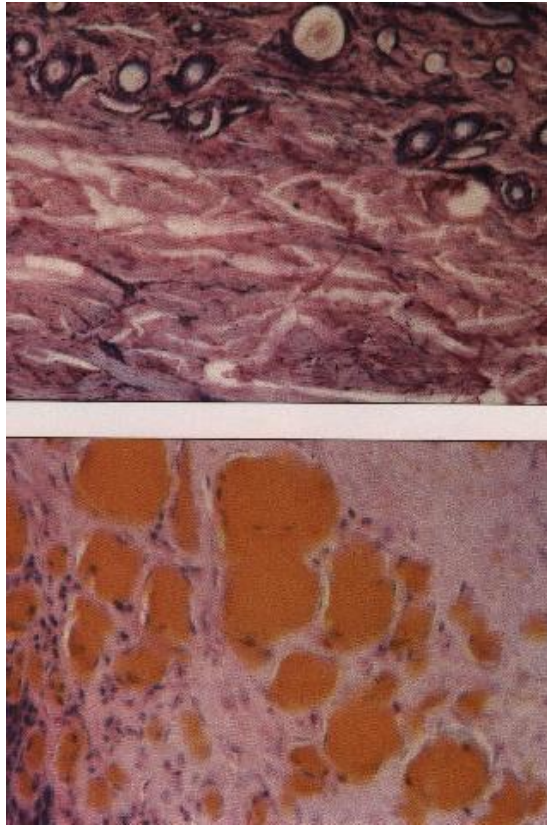
One of the first cases of animal mutilations (Picture above) reported was of an Apaloosa horse. It was found on September 9, 1967 in San Luis Valley, southern Colorado. A pathologist confirmed that all of the chest organs had been removed and the incisions had been made by high temperature. Cattle are usually the victims of the mutilators, but sometimes animals such as this horse (June 22, 1993 - Raymer, Colorado) are found.



This steer (Picture above) was found January 31, 1992 in Caldwell, Kansas. There seemed to be no blood loss from the extensive facial wounds and the hemoglobin was found to be cooked, ostensibly by whatever had done the cutting.



This calf (Picture above) was found in Harding County, South Dakota on May 26, 1993. The genitals, rectum, bottom lip, one ear, one eye and tongue were removed. Again, this was done with surgical precision, none of the wounds were jagged.



The top image (Picture above) shows normal cow blood. The bottom image shows blood removed from a mutilated cow. Note that the haemoglobin has been cooked in the second image. In addition to the heating of the wounds, many times the internal organs of mutilated animals are found to be dry, completely insanguinated.

End

--()--

12112008